ganda Journal of Agricultural Sciences, 2016. 17 (2): 197 - 217 ISSN 1026-0919 (Print)
ISSN 2410-6909 (Online)
rinted in Uganda. All rights reserved © 2016. National Agricultural Research Organisation

Uganda Journal of Agricultural Sciences by National Agricultural Research Organisation is licensed under a Creative Commons Attribution 4.0 International License.
Based on a work at www.ajol.info

# Histo-morphological description of the digestive system of the Rippon Barbel *Barbus altianals* (Boulenger 1900): A potential species for culture

*C. Aruho[1], V. Namulawa[1], C.D. Kato[2], M. Kisekka[2] J. Rutaisire[3] and F. Bugenyi[4]*

[1] National Fisheries Resources Research Institute, Kajjansi. P. O. Box 530, Kampala, Uganda
[2] College of Veterinary Medicine, Animal Resources & Biosecurity, Makerere University, P. O. Box 7062, Kampala, Uganda
[3] National Agriculture Research Organization, P. O. Box 295, Entebbe, Uganda
[4] Department of Zoology, Makerere University, P. O. Box 7062, Kampala, Uganda
**Author for correspondence:** caruho@yahoo.com

## Abstract

**Morphology of the digestive system can help define the feeding adaptation habits of a given fish species in a given environment. In a study to describe the nature and functionality of the digestive system of *Barbus altianalis*, samples of *B. altianalis* were taken from River Nile. Their Lengths and weights were measured and the gut structure preserved. The structure of the digestive tract of the *B. altianalis* was described using simple morphological observations and standard histological procedures. The digestive tube of *B. altianalis* is stomachless and valveless, progressively and uniformly reducing in size from the proximal to distal end. The digestive tract is on average 2.22 ± 0.37 times longer than its body length. The mouth is terminal and protrusible and pharyngeal palatal organ is well developed. The last gill arch is modified into pharyngeal teeth and the eosophagus is short and muscular. Histological sections revealed the presence of taste buds from the lips to the cranial eosophagus and these regions of the digestive tract are lined by a stratified squamous epithelium. The intestines are lined by simple or pseudo stratified columnar epithelial layer which is highly folded. Goblet cells containing both acidic and neutral mucins are present throughout the entire digestive tract and are more numerous in the pharynx and the proximal part of the intestine. Lobes of pancreatic acini are discrete and scattered among liver cells, around the intestine and few are seen in the spleen surrounding blood vessels. Thus, the liver could most accurately be termed a hepatopancreas structure.**

**Key words: Goblet cells, hepatopancreas, intestine, mucins**

https://dx.doi.org/10.4314/ujas.v17i2.6

## Introduction

Morphology of the digestive system is a key aspect that defines the feeding adaptation habits of a given fish species in a given environment. Different fishes have different feeding habits and, are thus broadly classified into carnivores, detritus feeders, herbivores and omnivorous depending on what they eat (De Silva and Anderson, 1995; Rust, 2002). For this reason, different fishes have varying modifications of their digestive tracts for purpose of maximising nutrient uptake for survival and growth. The digestive morphology of several species has been studied to relate structural functionality with adaptation to feeding habits (Cataldi *et al.*, 1987; Murray *et al.*, 1996). Increased attention to such studies has primarily focused on the development of feeding technologies of candidate species for culture (Banan-Khojasteh, 2012).

In sub-Saharan Africa there is growing need to diversify and promote the culture of indigenous high-value fish species to increase fish production (Namulawa *et al.*, 2011; Rutaisire *et al.*, 2013; Kato *et al.*, 2014). Efforts were successful in artificially inducing one of the high value indigenous cyprinid, *B. altianalis,* to spawn (Rutaisire *et al.*, 2013). However, concern arose due to its slow growth rates that could partly be attributed to a knowledge gap of its feeding behavior. Cyprinids are largely cultured in Eurasia and contribute more than 70% of the total fish production (FAO, 2014). A number of cyprinids in Africa are potentially high-value species that are being ever exploited, and can only be salvaged through culture. Successful domestication and subsequent commercial culture of *B. altianalis,* will increase fish production and revenues for commercial farms in the region (Rutaisire *et al.*, 2013). The cyprinids, commonly referred to as carps, are regarded as stomachless fish though with a diversity of structural and functional modifications of the digestive system (De Silva and Anderson, 1995). Although the gastrointestinal tract in all vertebrates possesses stereotypical structural similarities, variation can occur between species (Domeneghini *et al.*, 1999; Buddington and Kuzmina, 2000); and hence great diversity in functionality (Banan-Khojasteh, 2012). Structural variations probably confer differences in digestive capabilities. Different regions along the gut with varying specialised characteristics maximise different physiological processes, to ensure uptake of nutrients (Buddington and Diamond, 1987; Dabrowisk and Celia, 2005). The purpose of this study was to describe the digestive system of *B. altianalis,* to provide insights into its functionality and feeding behavior, which will form a basis for developing feeding strategies for this fish under culture.

## Materials and methods

Two hundred ninety four *B. altianalis* specimens of body weight ranging from 58.3 to 8,300 g were collected from River Nile, at two close landing sites (00° 27´N; 33° 11´E and 00° 35´N; 33° 04´ E) along and close to the source of the River Nile, from July 2014 to January 2015. The specimens were collected using a long line of about 100 hooks of gap size 9-4, baited with Tilapia fingerlings, across a 10 m section of the River. The fish were killed by anaesthetising them with an overdose of AQUI-S solution (1 ml in 10 liters). They were weighed to the nearest 0.1 g using a digital weighing scale, and their lengths were measured to the nearest mm

by a calibrated ruler. All the fish were immediately dissected to expose the digestive system, through an incision made from the anus to the mouth. The extent of the mouth gap, the lengths of eosophagus and intestine, as well as the weight of the liver were recorded.

The mouth gap was measured using a Vernier caliper. Using this tool, 20 fish covering all size groups (58.3 – 8300 g) had the intestines and buccal pharyngeal sections removed and were immediately fixed in Bouin's solution for more than 48 hours before they were histologically processed. The remaining fish were immediately observed macroscopically to record and describe the gut features from the mouth to the anus. Photographs of the morphology of the digestive tract were taken, using a digital NV3, 4.2 V, 7. 2 megapixels Samsung camera.

From the fixed specimens, smaller sections were obtained from the oral cavity, the eosophagus, the intestine, the spleen and the liver. Tissue processing was accomplished following standard histological methods (Bancroft and Gamble, 2002). The processed sections were stained using Gill's haematoxylin and eosin (H & E) and/or Masson's trichome (MT). Periodic Acid Schiff (PAS) and Alcian Blue (AB; pH 2.5 and pH 1.0) stains were used on some tissues to identify the type of glycoconjugates in goblet cells along the digestive tract. The stained sections were examined using a Leica Micro-system microscope (Switzerland LTD, model PN: DM 500) at different magnifications. Photomicrographs were taken using a 10 mega pixels mounted canon digital Powershot camera (A640, China).

The relationship between the total length (TL) and the intestinal length (IL) and the mouth gap (GL), the liver weight (LW) and Body weight (BW) was determined by linear regression analysis, using Statistical Package for Social Sciences (SPSS) statistical version 20 (Armonk, NY: IBM Corp.). The relative gut index (RGI) was calculated by dividing IL by TL. To determine if there were differences in RGI among class sizes, ANOVA was performed and significant differences were estimated by Duncan's test at $p = 0.05$ confidence level, using SPSS. Mean values were recorded with standard deviations values as Mean ±SD.

## Results

**Gross morphology.** Macroscopic observations indicated that the digestive system of *B. altianalis* constituted a simple stomachless tube that could only be categorised into the head gut (mouth, pharyngeal and eosophagus) and the hind gut (intestine). The intestines were positioned ventrally to the gas bladder, which was immediately ventral to vertebrae column. On both sides of the digestive system, the bivalent gonads stretched from the upper peritoneal cavity near the septum alongside the digestive tract to the anal opening (Fig. 1a). The terminal mouth was protrusible (Fig. 1b, c). Its gap depth (from the upper to the lower lip) measured 0.9 cm in a small fish of 13.5, to 7.5 cm in a big fish of 84.3 cm standard length SL.

The mouth gap positively and strongly correlated with the TL (slope = 6.46; r=0.95, P< 0.001). The mouth had a rostral cap on the upper side, joined to the upper lip by a thin muscle layer that allowed flexibility in moving the mouth (Fig. 1c). Associated with the mouth were two pairs of short barbells, one on the rostral cap and the other at the end of the upper lip. There were four pairs of gill arches on

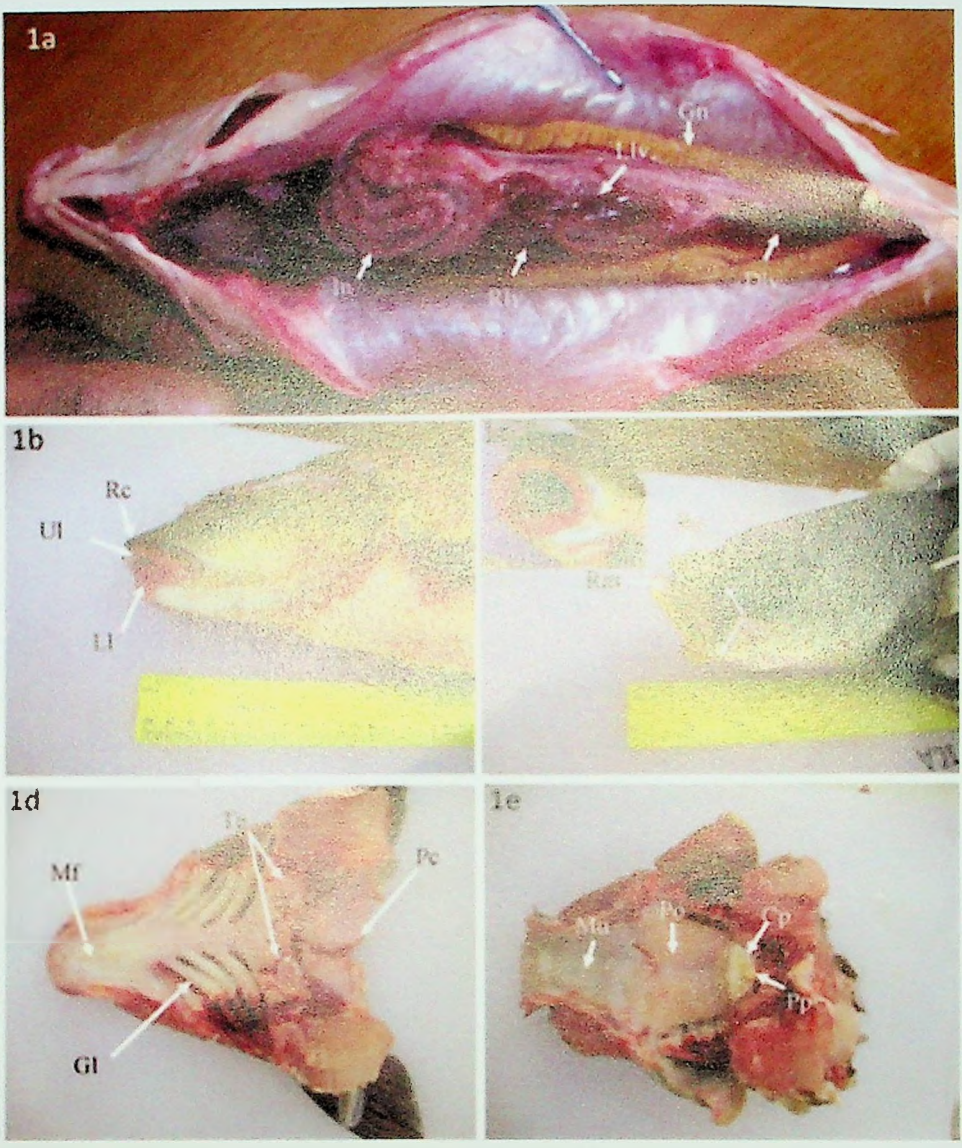


Figure 1. Gross anatomy of the digestive system of *B. altianalis*. In, intestine; Rlv, Right liver; Llv, left liver; Dlv, distal liver lobe; Gn, gonad; Rc, Rostral carp; Ul, Upper lip; Ll, lower lip; RM, Rostral membrane; Bb, Barbel; Mf, Mouth floor; Gl, gills; Te, Pharyngeal teeth; Pc, Pharyngeal cavity; Mu, Upper mouth cavity; Po, Palatal organ; Pp, Palatal protrusion; Cp, chewing pad.

either side of the buccal cavity. The oral cavity had no teeth but the fifth gill arch was modified into Pharyngeal teeth (8-11 in number) on either side (Fig. 1d). The roof of the oral cavity had ridges running parallel to each other towards the palate (Fig. 1e). The chewing pad was an ovoid shaped structure, located at the posterior end of palatal organ (Fig. 1e). At the caudal edge of the chewing pad, toward the eosophagus, was a palatal protrusion pointing to the ventral and perpendicular to the highly folded pharyngeal-funnel like pouch that narrowed toward the eosophagus (Fig. 1e).

The eosophagus was a short tough uniform tubular structure, continuous with the intestines and connected to the pharynx cranially (Fig. 2a). The eosophagus was positioned dorsal to the heart and transverse septum separating the heart from peritoneum. It constituted 0.65 ± 0.19% relative to the total intestinal length. The inner lining of the eosophagus had longitudinal strand-like rugae (Fig. 2b); while the outer surface was made of circular muscles that appeared as concentric rings. The outer surface gave the eosophagus a characteristic off-white colour that easily differentiated it from the much lighter and transparent intestine. In addition, a circular ring-like strand where the longitudinal rugae terminated caudally, was observed to mark the separation of the oesophagus and the intestine (Fig. 2b). At the cranial end of the eosophagus was a pneumatic duct that joined the eosophagus to the gas bladder midway the constriction separating the two halves of the gas bladder.

The small intestine was a coiled structure, with no clear macroscopic demarcations along its length. The intestine was coiled several times, forming a circular pattern located in the upper half of the peritoneal cavity beneath the gas bladder in a small fish; but as the fish grew bigger the intestinal coiling span the entire cavity up to the anus. The intestinal length was on average 2.22 ± 0.37 times longer than the total body length (TL). The TL was strongly correlated with IL (slope = 0.03; r =0.89, P < 0.001).

A statistical significance of RGI is observed between the individuals in lower class sizes of 20-29 cm and 30-40 cm TL; and the rest of other classes ($F_{4,290} = 8.014$, P<0.001; Table I). Generally, the small intestine decreased uniformly from cranial (proximal) intestine to distal intestine. There was no evidence identifying any distinct portions and any valves along the intestine. The inner surface of small intestine was thrown into mesh-like folds, spanning the entire length (Fig. 2b). In females and males with developing gonads in a reproductive cycle, large quantities of fats were visible surrounding and coiling alongside the intestine (Fig. 2c). The anus was clearly separated from the genital opening (Fig. 2d).

The liver was an elaborate brown coloured structure, with two clear large lobes. The liver formed 0.73 ± 0.23 % of the total body weight (BW) of the fish and showed a strong linear correlation with BW (Slope = 111.03; r=0.94, P < 0.001). The right lobe was longer and bigger than the left lobe, and stretched from the anterior side near the heart and eosophagus, down to the point just before the anus (Fig. 1a, 2e). The liver lobes were tightly joined to the intestines and the gonads by thin muscle-like strands and visible blood vessels. The gall bladder, between the liver and the intestines (Fig. 2e), possessed bile duct connecting cranially at about 1/3$^{rd}$ length of the main liver lobe.

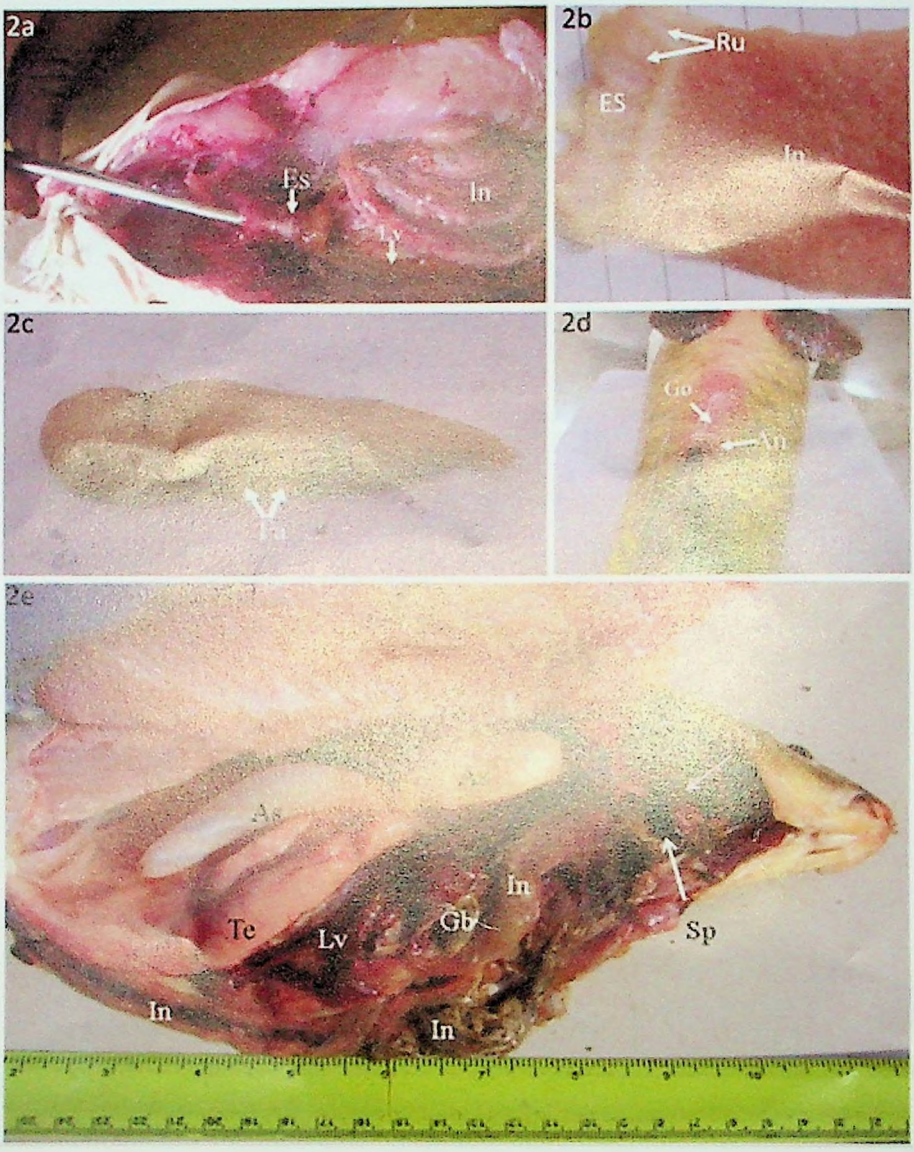


**Figure 2.** Gross anatomy of digestive tract of *Barbus altianalis*. Es, Esophagus; Ru, Rugae; Lv, liver; In, intestine; Fa, fat; Go, Genital opening; An, Anus; Gb, Gall bladder; As, Gas bladder; Sp, Spleen; Ha, Heart: Te, Testis.

*Histological description*

The lip was lined by a stratified squamous mucosa epithelium. Beneath, was a sub-mucosa layer made of collagen fibres. Underlying the sub-mucosa, fewer collagen fibres were interspaced with adipose cells (Fig. 3a). The collagens fibres made invaginations into the base of the mucosa epithelium, culminating into papillae-like fusiform structure that terminally formed the taste buds (Fig. 3a, b). The taste buds were interspersed with mucosa epithelial cells along the lips. These taste buds were also present on the barbells.

The arrangement of the layers in the oral cavity was similar to that of the lips; however, the layer underlying the sub-mucosa comparatively possessed fewer adipocytes. The adipocytes in this region were interspersed among striated muscle bundles (Fig. 4a, b). Taste buds were also interspersed in the epithelium of the oral cavity. Sparse mucous and club cells were visible within the mucosa-epithelium (Fig. 4a, d).

The pharynx had similar layers as those seen in the oral cavity, but with a highly folded mucosa, having numerous mucous goblet cells (Fig. 4d). Furthermore, there was evidence of sparsely scattered taste buds within the epithelium lining the pharynx, including that of the palatal organ. The layer beneath the mucosa epithelium in the pharyngeal region, retained characteristic mixture of dense striated muscles interspersed with connective tissue as observed in the oral cavity.

The oesophagus had four tunics, the mucosa, sub mucosa, muscularis and the serosa (Fig. 5a). The mucosa constituted the epithelium lining the lumen and the lamina propria. The oesophagus was lined with a stratified squamous epithelium at the cranial side that gradually turned pseudo stratified columnar in the middle

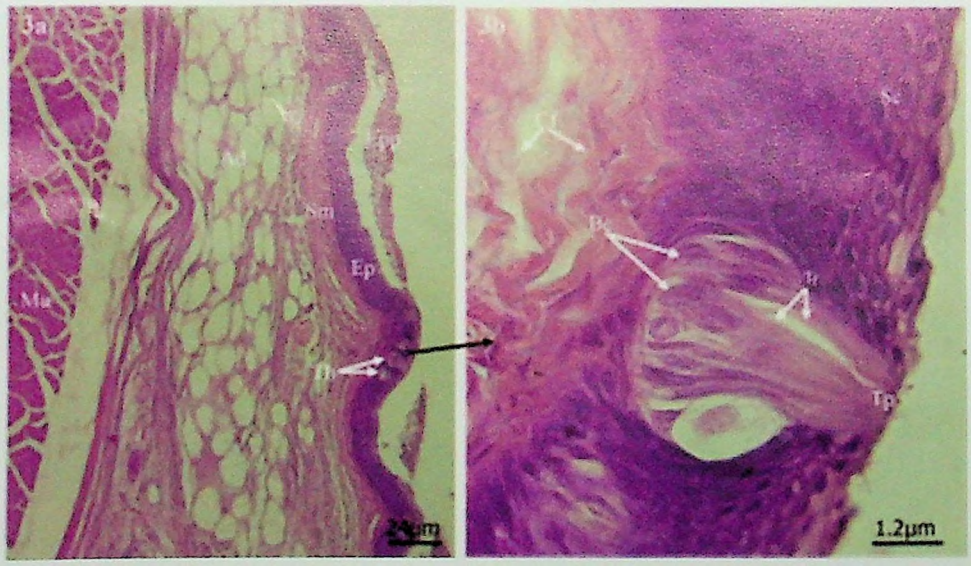


**Figure 3. Sections through the lips of *B. altianalis*. (a) Three layers of the lips are observed, mucosa epithelium (Ep), sub mucosa (Sm) and adipose tissue (Ad). Muscles (Mu), mucosa epithelial old cells (EPP) peeling off. (b) Magnified taste bud showing the taste pore (Tp), the basal cells (Bc) and taste receptors (Tr); Squamous (Sc). H and E.**

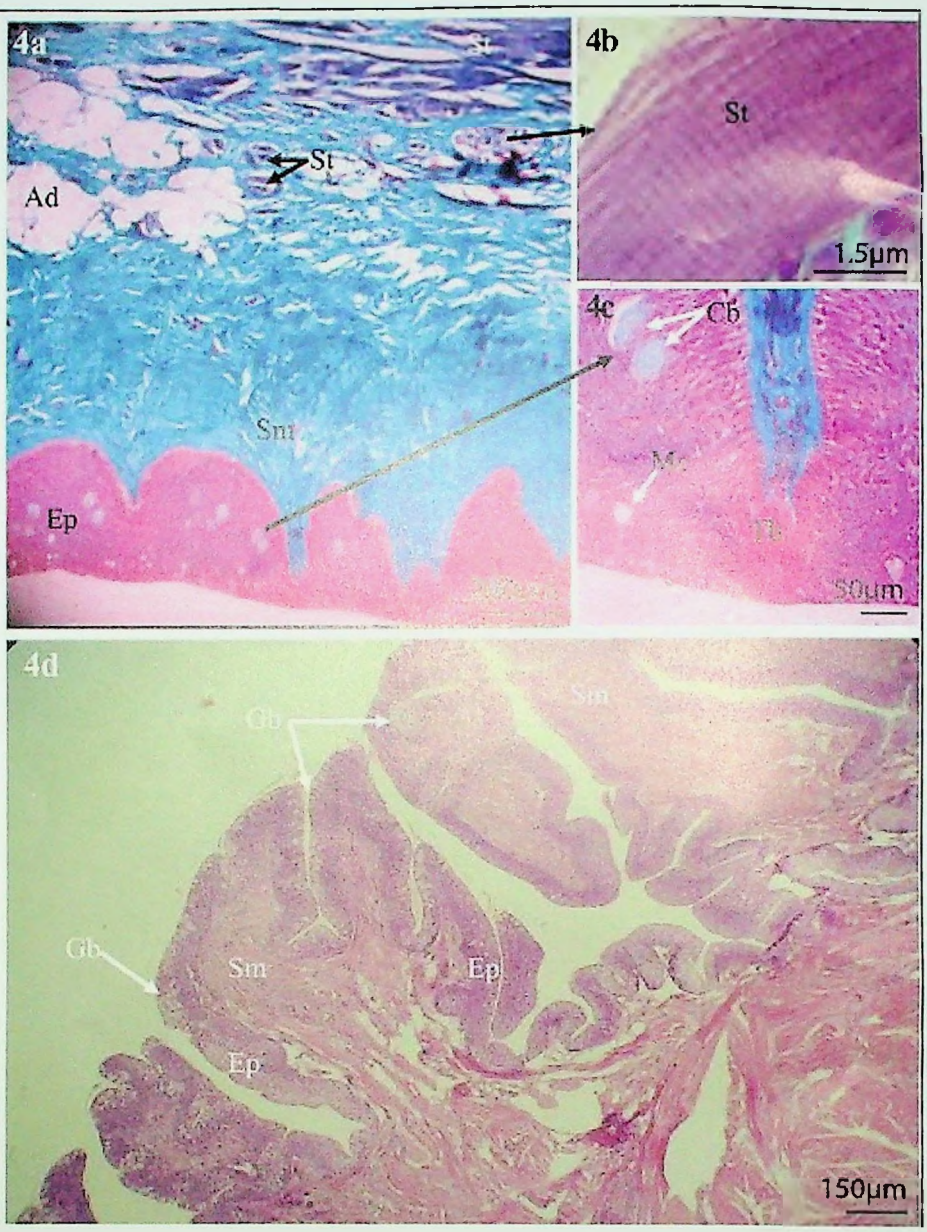


Figure 4. Sections through the oral and pharyngeal cavities. a) layers of the oral cavity, mucosa epithelium (Ep); the broad connective tissue of the sub mucosa (Sm), Adipose tissue (Ad) with the striated muscle bundles. MT. b) Magnified part of the oral cavity showing striated fibres (St). MT. c) epithelium is enlarged to show the taste bud (Tb) in the oral cavity, mucus cells (Mc) and the club cells (Cb). MT. e) highly folded epithelium (Ep) of the pharyngeal tissue with numerous goblet cells (Gb). H and E.

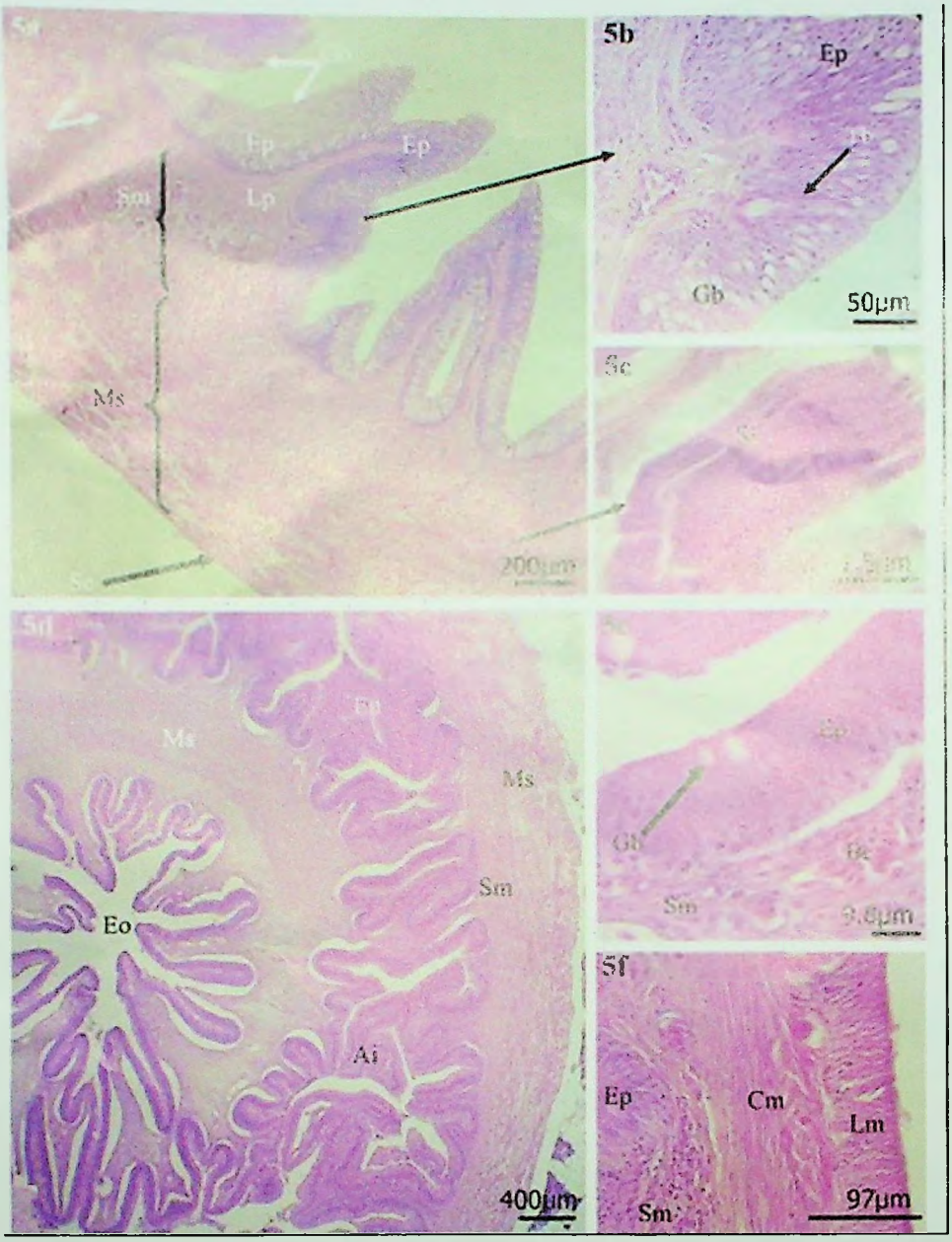


Figure 5. Sections through the eosophagus and anterior (cranial) intestine of *B. altianalis*. a) eosophagus tunics. The mucosa epithelium (Ep) with lamina propria (Lp), sub mucosa (Sm) with circular striated muscle bundles (Stc), muscularis (Mu) and serosa (Se). b) Magnified portion of mucosal epithelium showing stratified goblets (Gb) among epithelial cells and the taste bud (Tb) c) Magnified potion of Mu showing the striated muscle fibres (St). d) Sections cut at the transition junction between oesophagus (Oe) and the Anterior intestine (Ai) H and E. Both show columnar arrangement of epithelial and goblet cells in magnified section (e); Blood capillary (Bc) are also observed in (e). f) Magnification of muscularis layer in cranial intestine showing longitudinal muscle (Ls) and circular muscle (Cm). H and E.

and became columnar at the distal end. The stratified squamous epithelium at the cranial side of the eosophagus was largely dominated by goblet cells, but the goblet cells were comparatively fewer among the columnar cells at the distal end (Fig 5a, b, c,).

Taste buds were still evident at the cranial region of the oesophagus, but were absent in the rest of the oesophagus (Fig. 5b). The sub-musosa was generally thin beneath the lamina propria and was composed of loose connective tissue of collagen fibers interspersed with small circular bundles of striated muscle. The sub-mucosa lay over a thick wide muscularis. The muscularis appeared as a single layer. However, in cross-sectioned tissues, it was observed to constitute interdigitation of both circular and longitudinal striated muscle bundles (Fig. 5a, c), occasioned by an arrangement of some connective tissue fibres.

The adjacent muscularis of the cranial intestine was not a single layer as in oesophagus but had longitudinal and circular subdivisions (Fig 5f). At the distal end of oesophagus adjoining the intestine, where morphologically a ring was observed, the muscularis was much thicker compared to the rest of the Oesophagus. Beneath the muscularis was a thin layer, serosa.

The histological organisation of intestinal tract layers remained relatively the same from the oesophagus to the anus, with some differing structural details. Epithelial folds were comparatively deeper in the intestine and reduced toward the distal intestine, with the folds becoming narrower and smaller, but relatively deeper only around the rectum and the anus. Although the extent of the epithelial folds differed along the entire length of the intestine, the epithelium comprised of largely columnar cells with regularly dispersed goblet cells and enterocytes.

A brush border that constituted microvilli was observed at the luminal surface of the enterocytes and numerous eosinophils (leucocytes) spanned the entire lamina propria of the intestine (Fig. 6a). The goblet cells constituted both neutral and acidic glycoconjugates (mucins), along the digestive tract. These mucins occurred together within the same goblet cell, a reason why sections stained with (AB PH 2.5)-PAS combination largely showed dark purple colouration for the goblet cells indicating double staining (Fig. 6b). However, staining with AB (pH 1.0 and 0.5) was strongly observed with a deep blue colouration and numerous within the pharyngeal cavity and moderately stained in oesophagus. This indicated the presence of sulphated glycoconjugates in this region. These goblets were very few and weakly stained blue along other regions of the digestive system.

Unlike the oesophagus, the intestinal sub-mucosa was devoid of the striated muscle bundles and had a wavy arrangement of the loose connective tissue along the entire intestinal length (Fig. 6c). Similarly, whereas mascularis in the oesophagus was not subdivided, the intestinal muscularis had two clear tunics of the inner circular layer and the outer longitudinal muscle layer. The inner circular layer was thicker than the outer longitudinal layer, throughout the intestinal length and the two layers were separated by a thin layer consisting of largely nerve plexus (Fig. 6c). The muscularis of the first portion of anterior intestine (about 1 cm) adjacent to the oesophagus retained some circular and longitudinal striated muscle fibres found in the oesophagus. The rectal muscularis lacked muscle

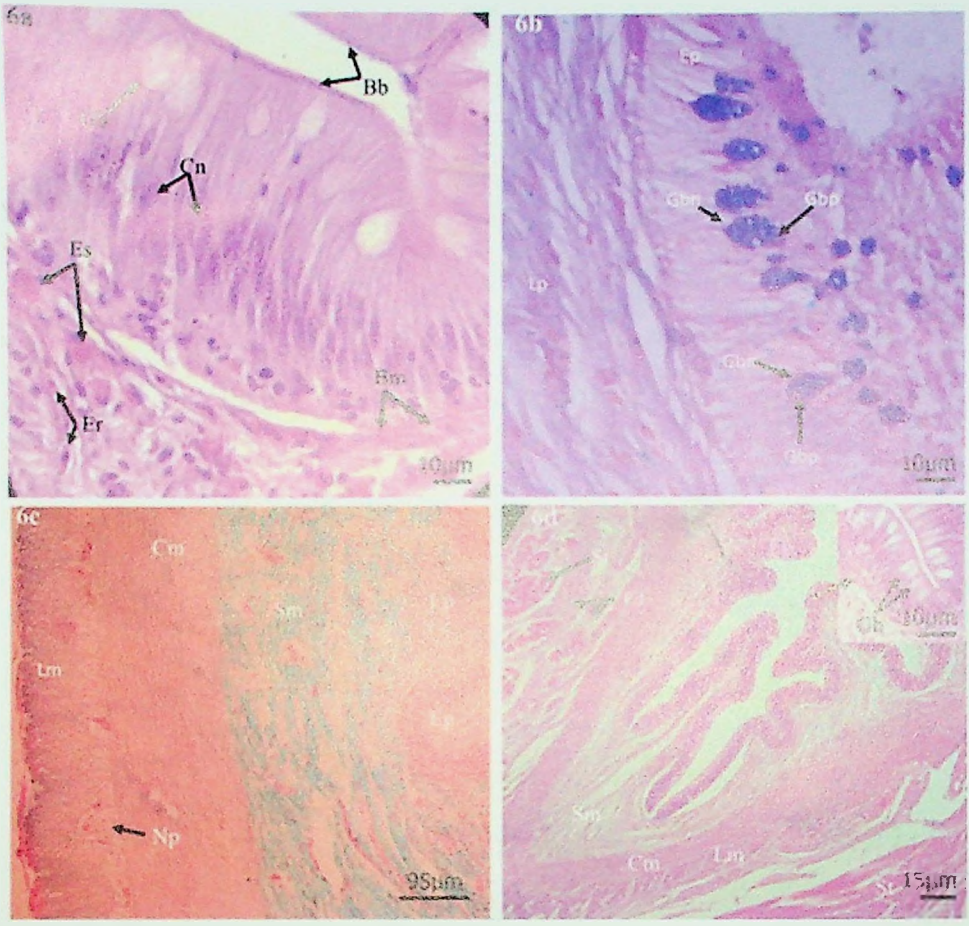


**Figure 6. Sections through the intestine and the rectum. a) Mucosa epithelium showing columnar cells with elongated nucleus (Cu), interspersed with goblet mucous cells (Gb). Brash border microvilli (Bb), basement membrane (Bm), oesinophilis and the erythrocytes (Es). H & E. b) goblet mucous cells (Gb) stained positive with PAS and AB pH 2.5. The figure shows two superimposed colors in each globule indicating presence of neutral mucins (Gbn) staining purple and acidic mucins (Gba) staining blue. (c) Broad sub mucosa (Sm) with wavy loose connective collagen fibres stained blue. Nerve plexus (Np) are between the inner circular layer (Cm) and the outer longitudinal layer (Lm), MT. d) Rectal circular muscle (Cm) adjoined to a layer of striated muscle (St) and connective tissues (Ct). e) Single columnar epithelium is observed with numerous globules (Gb)**

striations, but beneath it the collagen tissue and blocks of striated muscles were observed (Fig. 6d). The serosa beneath the muscularis remained very thin from the proximal to distal intestine. However, its clarity disappeared close to the rectum and the anus.

The liver hepatocytes were arranged in anastomosing cords towards the central vein. The hepatic cords were interspaced by numerous sinusoids oriented toward the direction of central veins (Fig. 7a.). The arrangement depicted a roughly hexagonal shape constituting a lobule with

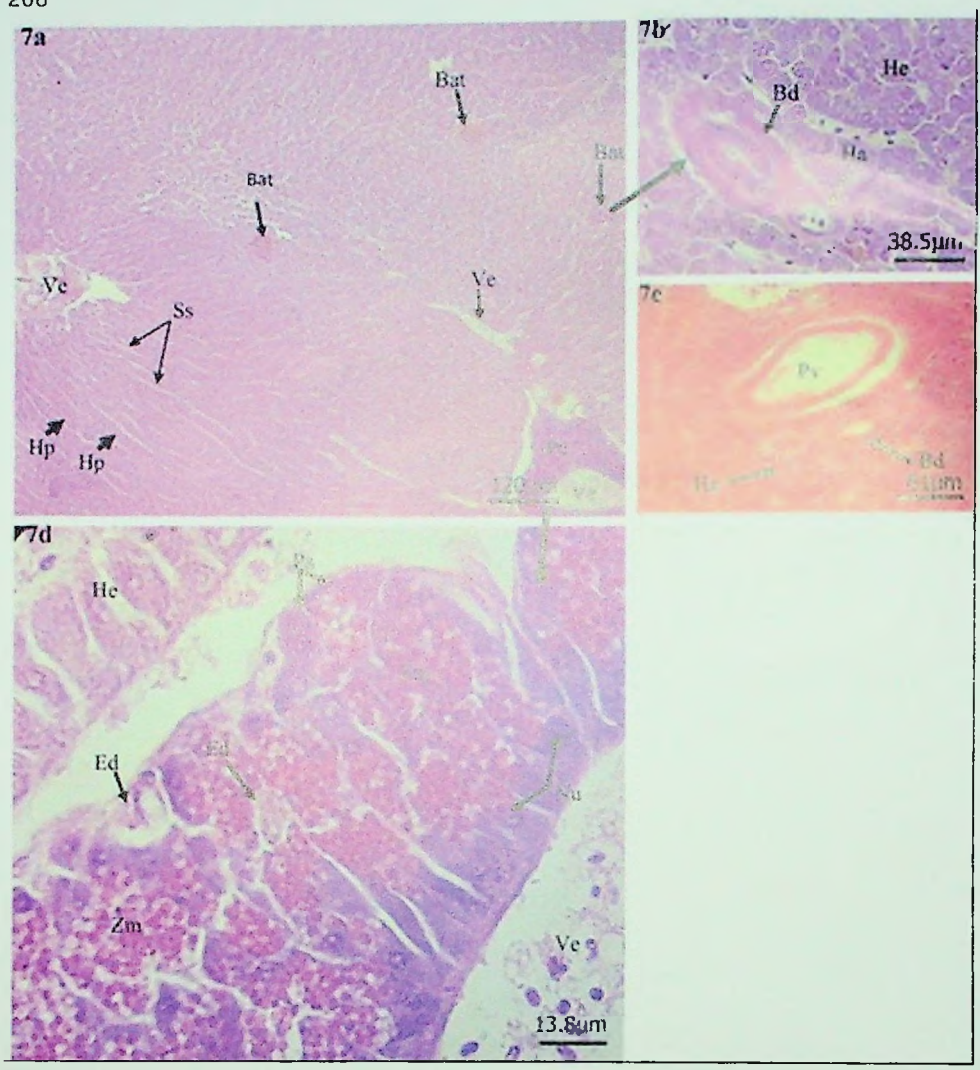


Figure 7. Sections through the liver of *B. altianalis*. a) Anastomosing pattern of hepatocyte plates (Hp). The arrangement orients toward the central veins (Ve) and is reflected by the narrow empty spaces, the sinusoids (Ss). The biliary-arteriolar tracts (Bat) are commonly observed in the liver parenchyma. Pancreas (Pc) is present in the liver. b) Magnified section of liver (7a) showing biliary-arteriolar tract constituting the bile duct (Bd) and the hepatic arteriole (Ha). c) A liver section with a portal triad consisting of bile duct (Bd), hepatic arteriole (Ha) and portal venule (Pv). d) A magnified section of the liver (6a) showing pancreatic acinar (Pa), exocrine zymogen granules (Zm), endocrine pancreas (Ed) and Acinar nucleus (Nu). H and E.

unclear demarcation. Within the liver, parenchyma were tracts of hepatic venules, the bile ducts and the hepatic arterioles (Fig. 7b, c). Pancreatic acini constituted triangular, polygonal, pyramidal or rhomboid shaped acinar with a basal located eosinophilic nucleus.

The inactive zymogen granules were observed packed within the acinar (Fig. 7d). The pancreatic tissue appeared as oval or longitudinal mass within the liver parenchyma, and formed a hepato-pancreas (Fig 7a. d). The pancreatic acini were formed around the veins. In a number of sections the pancreatic acini were commonly observed in contact with the intestines in mesentery along its entire length (Fig. 8a). Pancreatic tissue was also observed in spleen around the veins (Fig. 8c).

## Discussion

Morphological and histological observations confirmed that *B. altianalis* species has a general simple stomachless digestive structure characteristic of most cyprinids (Hofer, 1991; Delashoub *et al.*, 2010); though with some structural details unique to the species. The protrusible and flexible mouth (Fig. 1) suggests that this fish shows greater flexibility in its feeding strategy along the water column, including the ability to feed on the detritus material and other bottom dwellers. The fact that the bottom molluscs, crustaceans, detritus, planktons and small fish form part of the fish's diet (Balirwa, 1979) confirmed its feeding flexibility. The Relative Gut Index RGI (2.22 ± 0.37), coupled with the dietary composition; absence of stomach and the nature and pattern of the mucins present in the goblet cells classified *B. altinalis* as a typical omnivorous fish. This feeding behavior is also observed in other similar cultured omnivorous cyprinid, *Cyprinus carpio* whose RGI is estimated to be between 1.8 -2.0 (De Silva and Anderson, 1995).

The RGI of most omnivorous fish species ranges between 0.8-5 (Rust, 2002). Takeuchi *et al.* (2002) suggested that the noted RGI in common carp was effective in utilising and deriving sufficient energy for growth from both carbohydrate and lipid or protein food sources. However, in other *Burbus* species such as *Barbus sharpeyi* and *Barbus gryppis*, the RGI was recorded between 2·79- 3·18 and 2·00- 2·76, respectively (Al-Hamed, 1965). These are plant feeders, but have an RGI close to that of *B. altianalis*. This possibly illustrate phylogenetic diversion from the ancestors, meant to exploit diverse feeding environments. Current studies are using evolutionary history and phylogeny approach to interpreting gut morphometries such as gut index, in order to classify closely related species of diverging feeding behavior (German *et al.*, 2006; Wagner *et al.*, 2009). Such approach could be useful to establish feeding relationships of *B. altianalis* with other species of the same genus. The significant variation in RGI observed in the lower class sizes could suggest a transient feeding mode in this species, preferring a live feed dominated deity in its juvenile stages. This behavior could suggest investigating the possibility of fish nutritional requirements at varying stages of development.

The presence of numerous taste buds interspersed among the mucosa epithelial cells on the barbells, the lips, the oral-pharyngeal cavities and the oesophagus (Figs. 3 and 4), illustrated their strong gustatory role in this region, suggesting the increased fish's ability to scan the

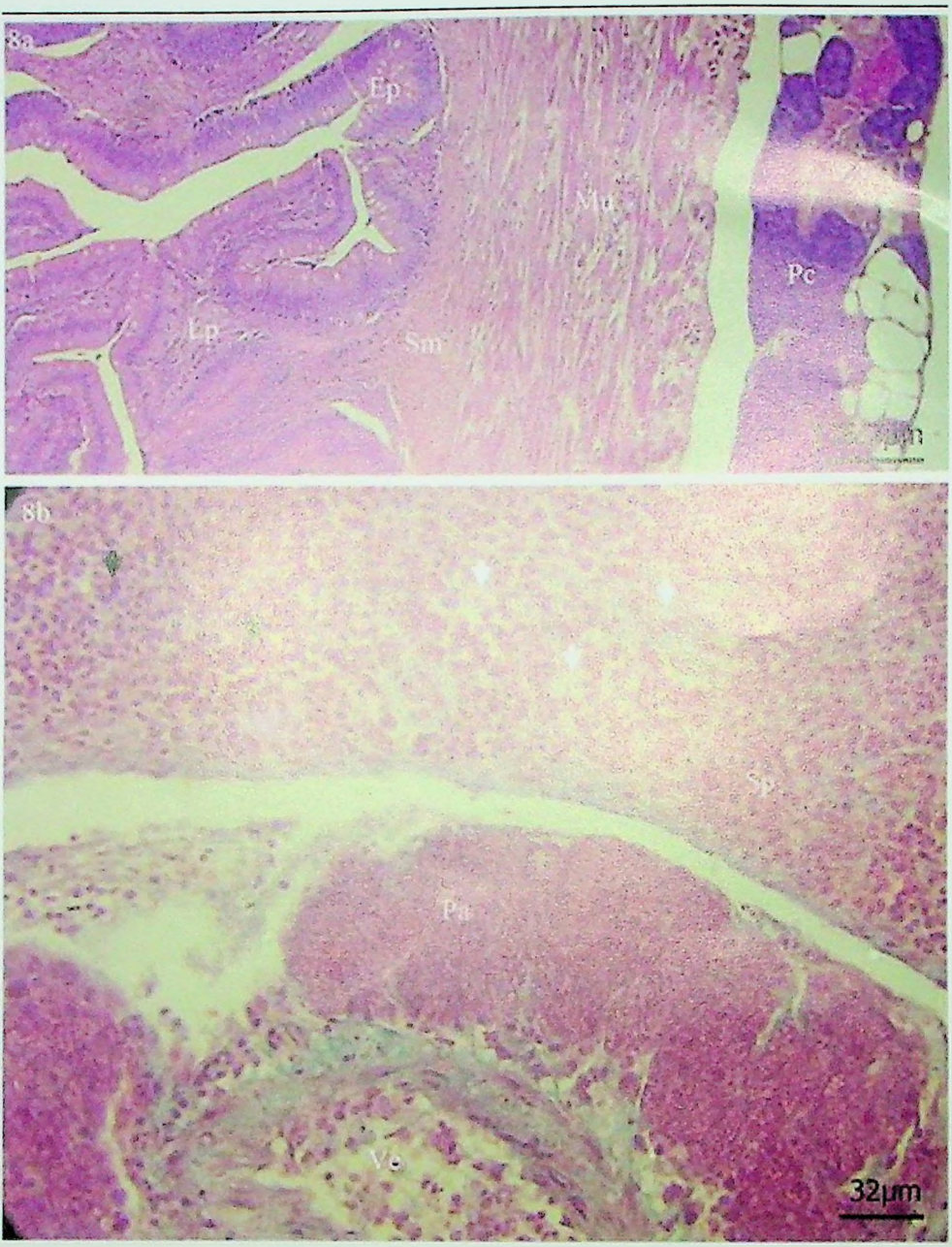


**Figure 8.** Sections through the intestine and the spleen. a) pancreatic tissue (Pc) around the intestine. H and E. b) Pancreatic acini (Pa) within the spleen (Sp), seen around the Vein (Ve). White pulp (white arrows) and Red pulp (black Arrows) are observed. MT.

environment for its preferred food items. The taste buds on the barbells suggested a hunting behavior or search for its food items as observed by Fox (1999) on a number of barbelled fish species. The barbells formed part of extra oral gustatory system that enhances the role of incitants and suppressants in fish, used to search and grasp the preferred food items before they are passed on to the oral- pharyngeal system that enhances stimulation for food palatability (Mearns *et al*., 1987; Kasumyan and Doving, 2003).

The presence of this system in *B. altianalis* equally suggests a selective behavior for preferred items, thus necessitating addition of stimulants to artificial feeds to enhance stimulation and palatability for food items, a common practice for some cultured species (Kasumyan and Doving, 2003). The palatal organ at the roof of the buccal cavity was well developed, as represented in some cultured carps such us *Cyprinus capio;* and is associated with the mechanical separation of food items from inorganic debris during feeding (Sibbing, 1982; Osse *et al*., 1997).

Callan and Sanderson (2003) illustrated an important additional role of chemosensory function of the palatal organ. Chemosensory function is initiated by the presence of taste buds to aid formation of wavy protrusions across the organ for expelling inorganic particles and retaining small food particles as well. The absence of the tongue at the floor of the mouth cavity illustrated inability of the fish to masticate the food items, a common challenge in most fishes (Namulawa *et al*., 2011). The tongue is replaced by taste buds for gustatory role as observed in *Cyprinus carpio* (Curry, 1939; Kasumyan and Morsi, 1996; Farag *et al*., 2014), as well as the *Catla catla* and *Barbus stigma* species (Kooper, 1957). However, the presence of pharyngeal teeth and the palatal chewing pad in pharyngeal cavity made effective machinery for grinding the food items. This was further strengthened by histological revelation of deep mucosa folds with numerous epithelial goblet cells in the pharyngeal cavity, that offered lubricating role and facilitating smooth movement for the crashed food items. The posterior palatal protrusion on the chewing pad, was perpendicular to the eosophagus opening and acted as a stopper' by preventing the backflow of food items into pharyngeal cavity.

The noted tough short oesophagus with its numerous epithelial goblet mucous cells seems to facilitate a quick swift movement of the crushed feed material into the intestine. The increased number of goblet mucus cells in the buccal pharyngeal cavity and the oesophagus in fish species, is generally an adaptation that compensates the absence of salivary glands found in other vertebrates to facilitate food lubrication and movement (Cataldi *et al*., 1988; Albrecht *et al*.,, 2001; Abd El Hafez *et al*., 2013).

The striated muscle fibres and rugea observed in the oesophagus (Figs. 2b and 5) offered flexibility in expanding, contracting and containment of pressure exerted on it by the food items and allow the movement of the food material into the intestine. The presence of striated muscles has been reported to perform similar functions in some species (Albrecht *et al*., 2001; Dai *et al*., 2007; Namulawa *et al*., 2011).

The oesophagus was comparatively smaller in size than the adjacent proximal intestinal tube, suggesting an additional role of effectively preventing the back flow of food items. The presence of taste buds in the cranial part of the oesophagus

has been also reported in some species such as sturgeon (Domeneghini *et al.*, 1999), and in grass carp, *Ctenopharyngodon idella* (Abd El Hafez *et al.*, 2013). Their presence indicated that unpalatable food items could still be expelled.

The effectiveness of digestibility of food along the digestive tube of *B. altianalis* was enhanced and facilitated by the presence of both neutral and acidic mucins within the goblets cells (Fig. 6b). The acidic mucins were dominated by the sialyted glycoconjugates that stained positive with AB pH 2.5. Both neutral and sialyted mucins are responsible for the less viscous mucal characteristic nature that largely facilitates lubrication and swift movement of food materials with in the gut system (Fiertak and Kilarski, 2002). They are also important in protection of the mucosa epithelia against harmful degrading pathogenic effects (Namulawa, 2014). The sialomucins have been found to protect the mucosa epithelia against the glycosidases degrading activity in fish species (Carrasson *et al.*, 2006) and also facilitate the conducive pH environment for appropriate enzymatic activity within the intestine (Traving and Shauer, 1998).

The increased presence of sulphated mucins in pharyngeal cavity than other regions of the gut illustrated their importance in the feeding process in this region. Tibbetts (1997) suggested that the sulphomucins are highly viscous and could help trap small particles. This observation seems to support the gustatory role and mechanical filtration process of food particles by the well developed palatal organ that aids retention of useful particles and the removal of unwanted materials from the buccal pharyngeal cavity. The entrapment of small food particles by mucus and their aggregation into boluses within the pharynx, was also reported in the common carp *Cyprinus carpio* (Sibbing and Uribe 1985). Mucins in cyprinids have been found to vary from one species to another and from one intestinal section to another, and could be influenced by the environment or feed formulations as well (Fiertak and Kilarski, 2002). This could further illustrate the flexibility in feed formulations for the newly domesticated *B. altianalis*, provided they are continuously improved to optimise the growth of fish. However, since the uptake capacity of nutrients by the intestine could be correlated with the natural diets in fish species (Buddington *et al.*, 1987), it is imperative that the feed formulation simulates that of the natural environment as close as possible.

Increased presence of enterocytes with epical brush border surface was noted in the proximal and the middle intestine (Fig.6a), where the mucosa epithelium forms deeper folds. Very few were observed in the rectal region. This indicated that these regions could represent the main site of digestion, where intestine effectively maximises the absorption of fine digested food material over a wide surface area before being expelled. The presence of enterocytes is typical of many fish species (Cyrino *et al.*, 2008), but their distribution along the gut varies among different species and they are a function of the mucosal epithelial folds, ensuring maximum absorption of nutrients (Murray *et. al.*, 1996; Cao *et. al.*, 2011). Numerous eosinophils in the lamina propria throughout the entire length of the intestine were crucial in containing pathogenic invasions from the intestinal lumen (Powell *et al.*, 1993).

The lobular structural arrangement of hepatocytes (Fig. 7) is similar to that of some fishes (Buddington and Kuzmina, 2000), but its outline is not well delineated with either connective tissue or the portal tracts as observed in higher vertebrates (Wheater *et al.*, 1979) as well as in some fish species such as the Nile perch *Lates niloticus* (Namulawa *et al.*, 2011). The presence of the numerous tracts in the liver (Fig. 7) ensure effective transportation of nutrients and exchange of metabolites through blood circulation around the hepatocytes plates. It was observed that in *B. altianalis*, the liver had a strong interdigitation of its tissue with the pancreas tissue making it a hepatopancreas. This arrangement has been observed in some cyprinids such as the common carp *Cyprinus carprio* (Takashima and Hibiya, 1995) and Crucian carp *Carassius auratus* (Yang *et al.*, 2009); as well as in some non cyprinid species (Brusle and Anadon, 1996; Namulawa *et al.*, 2011; Nejedli and Tlak Gajger, 2013). Furthermore, the presence of pancreatic acini spanning the entire length around the intestine within the mesentery (Fig. 8a) elaborates the critical role of exocrine and endocrine secretions during digestion. The interconnectivity of numerous blood vessels within and between the liver, with other visceral organs, is consistent with its many functions of largely ensuring the synthesis and distribution of the required body nutrients, as well as breakdown and removal of metabolites (Brusle and Anadon, 1996). The liver and mesenteric pancreatic tissue ensure utilisation and conversion of the large amounts of fat deposited around the intestines into energy during breeding as observed on some mature spawning fish in this study.

## Conclusion

This study has revealed the digestive structure of *B .altianalis* as a simple tube with less differentiated regions and that the general structure is consistent with that of other cyprinids. However, the location, the distribution and the glycoconjugates of goblet mucous cells, together with the variation pattern of the intestinal epithelial folds along the digestive tract may suggest some varying functional and physiological strategies unique to its feeding behavior. The flexibility in feeding along the water column and on various food items makes this fish a potential candidate for polyculture. The study suggests that, in spite of the omnivorous behavior, the described atributes form a basis for the continuous development or improvement of the available artificial feeds suitable for optimal growth rates. Such feeds could put into consideration a diet premised on age or size requirements under culture conditions.

## Acknowledgement

We appreciate the financial support from the World Bank fundcd project, the Agricultural Technology Advisory and Agribusiness Services (ATAAS). We thank the National Fisheries and Resources Research Institute (NaFIRRI), the Makerere University Colleges of CONAS and COVAB that provided other research facilities to make this work a success.

## References

Abd El Hafez, E.A, Mokhtar, D.M, Abou-Elhamd, A.S. and Hassan, A.H.S. 2013. Comparative histomorphological

studies on oesophagus of catfish and grass carp. *Journal of Histology* 1-10. Doi:10. 1155/ 2013/ 858674

Albrecht, M.P., Ferreira, M.F.N. and Caramaschi, E.P. 2001. Anatomical features and histology of the digestive tract of two related neotropical omnivorous fishes (Characiformes: Anostomidae). *Journal of Fish Biology* 58 (2): 419–430. Doi:10.1006/ jfbi.2000.1462.

Al-Hamed, M.I. 1965. On the morphology of the alimentary tract of three cyprinid fishes of Iraq. *Bulletin of the Iraq Natural History Museum (University of Baghdad)* 3:1- 25.

Banan-Khojasteh, S.M. 2012. The morphology of the post-gastric alimentary canal in teleost fishes: a brief review. *International Journal of Aquatic Science* 3(2):71-88.

Bancroft, J. D. and Gamble, M. 2002. *Theory and practice of histological techniques*, 5th edn. Churchill Livingston Publishers, Edinburgh, London, UK. pp. 85-107.

Balirwa, J.B. 1979. A contribution to the study of the food of six cyprinid fishes in three areas of the Lake: Victoria basin, East Africa. *Hydrobiologia* 66: 65-72.

Brusle, J. and Anadon, G.G. 1996. The structure and function of the liver In: J.S. Datta-Munshi, and H. Dutta, (Eds.), *Fish Morphology: Horizon of New Research*, Fish Brookfield, VT: CRC Press. pp. 79-94.

Buddington, R.K., Chen J.W. and Diamond, J. 1987. Genetic and phenotypic adaptation of intestinal nutrient transport to diet in fish. *Journal of Physiology* 393: 261–281.

Buddington, R.K. and Kuzmina,V. 2000. The digestive system. Ostrander, G.K. (eds.), In: *Handbook of Experimental Animals-The Fish*. 3(11): 173-178.

Buddington, R.K. and Diamond, J.M. 1987. Pyloric caeca of fish, a "new" absorptive organ. *American Journal of Physiology* 252: G65-G76.

Callan, W.T. and Sanderson, S.L. 2003. Feeding mechanisms in carp: cross flow filtration, palatal protrusions, and flow reversals. *Journal of Experimental Biology* 206: 883-892. Doi: 10.1242/ jeb.00195.

Cao, X. J., Wang, W.M. and Song, F. 2011. Anatomical and histological characteristics of the intestine of the Topmouth Culter (Culter alburnus). *Anatomia Histologia Embryologia* 40: 292–298.

Carrasson, M., Grau, A., Dopazo, L.R. and Crespo. S. 2006. A histological, histochemical and ultrastructural study of the digestive tract of Dentex dentex (Pisces, Sparidae). *Histology and Histopathology* 21: 579-593.

Cataldi, E., Crosetti, D., Conte, G., Ovidio, D.D. and Cataudella, S. 1988. Morphological changes in the esophageal epithelium during adaptation to salinities in *Oreochromis mossambicus, Oreochromis niloticus* and their hybrid. *Journal of Fish Biology* 32 (2): 191–196.

Cataldi, E., Cataudella, S., Monaco, G., Rossi, A. and Tansion, L. 1987. A study of the histology and morphology of the digestive tract of the sea-bream *sparus auratus*. *Journal of Fish Biology* 30:135-45. DOI: 10.1111/ j.1095-8649.1987.tb05740.x

Curry, E. 1939. The histology of the digestive tube of the carp (*Cyprinus carpio communis*). *Journal of Morphology* lxv: 53-78.

Cyrino, J.E.P., Bureau, D. and Kapoor, B.G. 2008. *Feeding and Digestive*

*Function of Fishes*. Science Publishers, Enfield, 575 pp.

Dabrowisk, K. and Celia., M.P. 2005. Feeding plasticity and nutritional physiology. In: W.S. Hoar, J.D. Randall and A.P. Farrell (Eds.), *Fish Physiology: The Physiology of Tropical Fishes*. Elsevier, Academic Press 21:155-224.

Dai, X., Shu. M. and Fang, W. 2007. Histological and ultra structural study of the digestive tract of rice field eel, Monopterus albus. *Journal of Applied Ichthyology* 23: 177-183. Doi: 10.1111/j.1439-0426.2006.00830.x

De Silva, S.S. and Anderson, T.A. 1995. *Fish Nutrition in Aquaculture*. Chapman and Hall, Landon, 319 pp.

Delashoub, M., Pousty, I. and Banan-Khojasteh, S.M. 2010. Histology of Bighead Carp *(Hypophthalmichthys nobilis)* Intestine, *Global Veterinaria* 5 (6): 302-306.

Domeneghini, C., Arrighi, S., Radaelli, G., Bosi, G. and Mascarello, F. 1999. Morphological and histochemical peculiarities of the gut in the white sturgeon, *Acipencer transmontanus*. European. *Journal of Histochemistry* 43:135- 145.

Fiertak, A. and Kilarski, W.M. 2002. Glycoconjugates of the intestinal goblet cells of four cyprinids. *Cellular Molecular Life Sciences* 59: 1724-1733. Doi 1420-682x/02/101724-10

Farag, F.M.M., Wally, Y.R., Daghash, S.M. and Ibrahim, A.M. 2014. Some gross morphological studies on the internal anatomy of the scaled common carp fish *Cyprinus carpio*) in Egypt. *Journal of Veterinary Anatomy* 7 (1): 15 – 29.

Food and Agriculture Organization (FAO). 2014. *The state of world fisheries and aquaculture*. World review of fisheries and aquaculture. FAO, Rome, Italy. 202 pp.

Fox, H. 1999. Barbels and barbel-like tentacular structures in sub-mammalian vertebrates: A review. *Hydrobiologia* 403: 153-193.

German, D.P. and Horn, M.H. 2006. Gut length and mass in herbivorous and carnivorous prickleback fishes (Teleostei: Stichaeidae): ontogenetic, dietary, and phylogenetic effects. *Marine Biology* 148: 1123-1134.

Hofer, R. 1991. Digestion. cyprinid fishes In: I.J. Winfield, and J.S. Nelson, (Eds.), *Systematics, Biology and Exploitation*. Chapman and Hall, London, UK. pp. 413–425.

Kasumyan, A.O. and Doving K.B. 2003. Taste preferences in fishes, *Fish and Fisheries* 4: 289-347.

Kasumyan, A.O. and Morsi, A.M.H. 1996. Taste sensitivity of common carp *Cyprinus Carpio* to free amino acids and classical taste substances. *Journal of Ichthyology* 36 (5): 391–403.

Kato, C.D., Nyatia, E., Matovu, E., Uni, Z., Kedar, O., Hakim, Y., Levavi-Sivan, B. and Rutaisire, J. 2014. Developmental changes in intestinal brush border enzyme activity in wild, juvenile Nile perch *Lates niloticus* (Linnaeus, 1758). *International Journal of Fisheries and aquaculture* 6 (6): 71-79. DOI: 10.5897/IJFA2013.0396.

Kooper, B.G. 1957. The study of the tongue of fishes. *Japanese Journal of Ichthyology* XII: 82-85.

Mearns, K.J., Ellingsen, O.F., Doving, K.B. and Helmer, S. 1987. Feeding behaviour in adult rainbow trout and Atlantic Salmon Parr, elicited by chemical fractions and mixtures of compounds identified in shrimp extract. *Aquaculture* 64: 47 63.

Murray, H.M., Wright. G.M. and Goff. G.P. 1996. A comparative histological and histochemical study of the post-gastric alimentary canal from three species of pleuronectid, the Atlantic halibut, the yellowtail flounder and the winter flounder. *Journal of Fish Biology* 48: 187- 206. Doi: 10.1111/j.1095-8649.1996.tb01112.x

Namulawa,V.T., Kato, C.D., Nyatia. E., Britz, P. and Rutaisire, J. 2011. Histomorphology description of the digestive system of Nile perch (*L. niloticus*). *International Journal of Morphology* 29 (3): 723-732.

Namulawa, V.T., Kato, C.D., Nyatia, E., Kiseka, M. and Rutaisire, J. 2014. Histochemistry and PM characterization of the gastrointestinal tract of nile perch *Lates niloticus*. *World Journal of Fish and Marine Sciences* 6 (2): 162-168.

Nejedli, S. and Tlak Gajger, I. 2013. Hepatopancreas in some sea fish from different species and the structure of the liver in teleost fish, common pandora, *Pagellus erythinus* (Linnaeus, 1758) and whiting, *Merlangius merlangus euxinus* (Nordmann, 1840). *Veterinary Archives* 83: 441-452.

Osse, J.W.M., Sibbing, F.A., Boogaart, J.G and Van den, M. 1997. Intra-oral food manipulation of carp and other cyprinids: Adaptations and limitations. *Acta Physiologica Scandinavica, Supplementum* 161 (638): 47-57.

Powell, M.D., Briand, H.A., Wright. G.M. and Burka, J.F. 1993. Rainbow trout *(Oncorhynchus mykiss)* intestinal eosinophilic granular cell (*EGC*) response to *Aeromonas salmonicida* and *Vibrio anguillarum* extracellular products. *Fish and Shellfish Immunology* 3: 279-289. Doi: 10.1006/fsim.1993.1027

Rust, M.B. 2002. Nutritional physiology. In: *Fish Nutrition*. J.E. Halver and R.W. Hardy, 3rd edn (eds.). Academic Press, London, UK. pp. 367–452.

Rutaisire, J., Levavi-Sivan. B., Aruho, C. and Ondhoro, C.C. 2013. Gonadal recrudescence and induced spawning in *Barbus altianalis*. *Aquaculture* 46 (3): 669–678. Doi:10.1111/are.12213

Sibbing, F.A. 1982. Pharyngeal mastication and food transport in the carp (*Cyprinus carpio* L.): A cineradiographic and electromyographic study. *Journal of Morphology* 172: 223–258. Doi: 10.1002/jmor.1051720208

Sibbing, F.A. and Uribe, R. 1985. Regional specialisation in the oral-pharyngeal wall and food processing in carp (*Cyprinus carpio* L.). *Netherlands Journal of Zoology* 35: 377-422.

Takashima, F. and Hibiya, T. 1995. An atlas of fish histology. *Normal and pathological feaiures*, 2nd ed, Kodansha Ltd, Tokyo, Japan. 195 pp.

Takeuchi, T., Satoh, S. and Kiron. V. 2002. Common carp, *Cyprinus carpio*. In: C.D.Webster and C. E. Lim (Eds.), *Nutrient Requirements and Feeding of Finfish for Aquaculture*. CABI Publishing. Oxon. pp. 245-261.

Tibbetts. I.R. 1997. The distribution and function of mucus cells and their secretions in the alimentary tract of *Arramphus sclerolepis krefftii*. *Journal of Fish Biology* 50, 809–820. Doi: 10.1111/j.1095-8649.1997.tb01974.x

Traving, C. and Shauer, R. 1998. Structure, function and metabolism of sialic acids. *Cellular Molecular Life Sciences* 54: 1330–1349.

Wagner, C.E., Peter, B.M., Kalmia, S.B., Danielle. M.G. and Ellinor, M. 2009. Diet predicts intestine length in Lake Tanganyika's cichlid fishes. *Functional Ecology* 23: 1122–1131. Doi:10.1111/j.1365-2435.2009.01589.x

Wheater. P.R., Burkitt, H.G. and Daniels, V.G. 1979. *Functional histology; A text and colour atlas*, 2nd ed. Church Hill Livingstone, London, 348 pp.

Yang, F., Su, W.J., Lu, B.J., Wu, T., Sun, L.C., Hara, K. and Cao, M.J. 2009. Purification and chemo characterization of chymotripsins from the Hepato pancreas of Crucian carp (*Carassius auratus*). *Food chemistry* 116 (4): 860–866.