No apparent differences in intestinal histology of channel catfish (*Ictalurus punctatus*) fed heat-treated and non-heat-treated raw soybean meal

J.J. EVANS[1], D.J. PASNIK[1], H. PERES[2], C. LIM[2] & P.H. KLESIUS[2]

[1] *Aquatic Animal Health Research Laboratory, United States Department of Agriculture – Agricultural Research Service (USDA-ARS), Chestertown, MD, USA;* [2] *Aquatic Animal Health Research Laboratory, United States Department of Agriculture – Agricultural Research Service (USDA-ARS), Auburn, AL, USA*

Abstract

The histopathologic effects of feeding heat-treated soybean meal to fingerling channel catfish (*Ictalurus punctatus*) were studied. Fish were fed one of six diets: a diet containing 450 g kg^{-1} commercial soybean meal (CSBM), or diets with the CSBM replaced by non-heat-treated raw soybean meal (RSBM0), or RSBM heated at 130 °C for 5 min (RSBM5), 10 min (RSBM10), 20 min (RSBM20) or 40 min (RSBM40). After 10 weeks, tissue samples were taken from the stomach, proximal intestine, distal intestine, liver, pancreas and spleen from fish in each group for histologic examination. Mild necrotic lesions were found in the gastric glands, pancreas and liver of fish in all the groups (treatment and control groups). Hepatic glycogen deposition was also observed in all the groups, and the spleen samples exhibited considerable brownish-black pigment deposition around the splenic corpuscles and diffuse mild-to-moderate congestion in all of the groups. Generally, these histologic effects appeared to be equivocal between all of the groups, and no abnormalities were noted in the proximal or distal intestine. These findings suggest that feeding channel catfish a diet containing 450 g kg^{-1} non-heat-treated RSBM did not cause severe histologic changes associated with soybean meal anti-nutritional factors as have been reported in salmonids.

KEY WORDS: diet, fish, histology, intestine, nutrition, soybean meal

Received 21 January 2004, accepted 19 October 2004

Correspondence: Dr David J. Pasnik, Aquatic Animal Health Research Laboratory, United States Department of Agriculture – Agricultural Research Service (USDA-ARS), 151 Dixon Drive, Chestertown, MD 21620, USA. E-mail: dpasnik@msa-stoneville.ars.usda.gov

Introduction

Considerable effort has been placed on developing alternative protein sources for aquaculture diets to replace fishmeal. Soybean meal (SBM) is the most commonly utilized plant protein in fish feeds, because it is inexpensive, available, palatable, and has high nutritional value (Lim & Akiyama 1991; Peres *et al*. 2003). However, inclusion of high levels of SBM in fish diets has led to adverse effects, such as reduced growth rates and feed utilization efficiency (Beckmann & Pfeffer 1989; Lim & Dominy 1989). These poor growth responses have been widely attributed to several factors, including the presence of anti-nutritional factors. Many of the anti-nutritional factors found in raw SBM (RSBM) are heat-labile, and heat-treatment of the RSBM during processing can inactivate most of these factors. However, heat-treatment can add considerable cost to processing and reduce the availability of other nutrients (Kratzer *et al*. 1990; Qin *et al*. 1998). Thus heat-treatment should be kept to a minimum as determined by the balance between inactivation of anti-nutritional factors and destruction of nutrients.

The histologic changes in animals fed diets containing various soybean products have been examined, and some fish species appear to be considerably sensitive to the effects of soybean anti-nutritional factors (Krogdahl & Holm 1983; Dimes *et al*. 1994). Other studies have indicated that salmonids fed SBM have had severe pathologic changes in the intestinal mucosa (van den Ingh *et al*. 1991; Rumsey *et al*. 1995). However, prior studies have concentrated on the intestinal changes and not on the effects of RSBM on other internal organs. Furthermore, histologic changes among channel catfish (*Ictalurus punctatus*) fed RSBM have not been assessed, nor have these changes been compared with those in fish fed heat-treated RSBM or dehulled, solvent-extracted SBM. Therefore, the study presented here endeavoured to

© 2005 Blackwell Publishing Ltd

determine the effects of feeding RSBM and heat-treated RSBM to channel catfish according to histologic changes in a number of internal organs.

Materials and methods

Experimental diets and fish

Six practical-type diets were formulated and fed to fingerling channel catfish (*I. punctatus*) as described in Peres *et al.* (2003). The diets were isocaloric (2.8 kcal kg^{-1} diet) and isonitrogeneous (340 g kg^{-1} crude protein). A diet with 450 g kg^{-1} dehulled, solvent-extracted commercial SBM (CSBM) was included as a control. Defatted, dehulled raw soybean meal (RSBM; Cargill Protein Products, Cedar Rapids, Iowa, USA) was utilized to replace the CSBM in the control diets on an equal-protein basis. The resulting experimental RSBM was non-heat treated (RSBM0), or heated in an autoclave at 130 °C and 22 psi for 5 min (RSBM5), 10 min (RSBM10), 20 min (RSBM20) or 40 min (RSBM40). The ingredients were finely ground, mixed in a Hobart mixer, and pelleted through a Hobart meat grinder; the resulting pellets were air dried at room temperature, broken into appropriate pieces, and frozen at −8 °C until used. The composition and proximate analysis of the experimental diets are presented in Table 1.

Non-immunized, *Edwardsiella ictaluri* and *Flavobacterium columnare*-free USDA-ARS strain 103 channel catfish with an average weight of 4.98 ± 0.09 g were randomly selected and stocked into 110 L flow-through aquaria at 50 fish per aquarium. The aquaria were supplied with dechlorinated city water at a rate of approximately 0.5 L min^{-1} and increased gradually to approximately 1 L min^{-1} by the end of the study. The fish were maintained on a 12 : 12 h light : dark photoperiod schedule with an average dissolved oxygen level of 6.2 ± 0.6 mg L^{-1} and an average temperature of 25.4 ± 0.1 °C. Fish in randomly assigned triplicate aquaria were fed one of the six experimental diets to apparent satiation twice daily for 10 weeks.

Histologic examination

After 10 weeks, three fish from each of the triplicate aquaria were randomly selected and humanely euthanized by cervical dislocation. Tissue samples were taken from the stomach, liver, pancreas, proximal intestine, distal intestine and spleen. Based on anatomical descriptions by Gammon (1970) and Grizzle & Rogers (1976), the proximal intestine was sampled between the pyloric sphincter and the first intestinal loop, while the distal intestine was sampled between the last intestinal loop and the anus. All tissue samples were fixed in Bouin's, embedded in paraffin, sectioned at 5 μm, and stained with Harris' haematoxylin and eosin (H&E) (Luna 1968).

Histologic samples from the stomach, proximal intestine, distal intestine, pancreas, liver and spleen of sampled fish in each treatment group were examined and compared with normal channel catfish tissue morphology as described by Grizzle & Rogers (1976) and to histologic samples from

Mention of trade names or commercial products in this publication is solely for the purpose of providing specific information and does not imply recommendation or endorsement by the US Department of Agriculture.

Table 1 Composition and proximate analysis of the experimental diets (from Peres *et al.* 2003)

	Diet (g kg^{-1})					
Ingredient	CSBM	RSBM0	RSBM5	RSBM10	RSBM20	RSBM40
Menhaden fishmeal	80.0	80.0	80.0	80.0	80.0	80.0
CSBM	450.0	–	–	–	–	–
RSBM0	–	450.0	–	–	–	–
RSBM5	–	–	450.0	–	–	–
RSBM10	–	–	–	450.0	–	–
RSBM20	–	–	–	–	450.0	–
RSBM40	–	–	–	–	–	450.0
Constant components	470.0	470.0	470.0	470.0	470.0	470.0
Proximate analyses (g kg^{-1})						
Moisture	94.6	98.5	106.9	107.2	99.8	97.5
Crude protein	338.5	344.6	344.8	344.1	348.2	349.1
Crude fat	64.8	59.8	61.1	60.5	64.5	62.1
Ash	77.2	78.3	78.2	78.7	79.0	78.6

CSBM, commercial soybean meal; RSBM, raw soybean meal; RSBM0, non-heat-treated RSBM; RSBM5, RSBM autoclaved at 130 °C and 22 psi for 5 min; RSBM10, RSBM autoclaved at 130 °C and 22 psi for 10 min; RSBM20, RSBM autoclaved at 130 °C and 22 psi for 20 min; RSBM40, RSBM autoclaved at 130 °C and 22 psi for 40 min.

Constant components (g kg^{-1}): corn meal, 340.0; wheat middlings, 50.0; cod liver oil, 30.0; dicalcium phosphate, 10.0; trace mineral mix, 5.0; vitamin mix, 5.0; carboxymethyl cellulose, 30.0.

Trace mineral mix provided the following minerals (mg kg^{-1} diet): zinc (as $ZnSO_4 \cdot 7H_2O$), 150; iron (as $FeSO_4 \cdot 7H_2O$), 40; manganese (as $MnSO_4 \cdot H_2O$), 25; copper (as $CuCl_2$), 3; iodine (as KI), 5; cobalt (as $CoCl_2 \cdot 6H_2O$), 0.05; selenium (as Na_2SeO_3), 0.09.

Vitamin mix provided the following vitamins (mg kg^{-1} diet unless otherwise stated): vitamin A, 4000 IU; vitamin D_3, 2000 IU; vitamin K, 10; vitamin E, 50; thiamin, 10; riboflavin, 12; pyridoxine, 10; panthothenic acid, 32; nicotinic acid, 80; folic acid, 2; biotin, 0.2; vitamin B_{12}, 0.01; choline chloride, 400; L-ascorbyl-2-polyphosphate (150 g kg^{-1} vitamin C activity), 60.

channel catfish maintained on a floating 280 g kg^{-1} fishmeal-based diet (Delta Western, Indianola, MS, USA). Histologic changes were scored according to both their distribution (focal, multifocal, diffuse) and severity with an arbitrary numerical scale. The scale was defined as score 0, non-existant; 1, mild; 2, moderate; 3, severe; mild lesions had little impact on the observed organ while severe changes involved significant alteration of its appearance or architecture. These numbers were then utilized to determine an overall severity score for each sampled tissue in each sampled fish and treatment group.

Statistical analysis

Data on weight gain, feed intake, feed efficiency ratio and survival were subjected to a one-way analysis of variance (ANOVA) using the general linear model procedure of SAS (SAS Institute, Cary, NC, USA). Significant differences for the overall severity scores were determined using the van der Waerden test. Differences were considered significant at $P = 0.05$.

Results

Nutritional values of heat-treated RSBM were previously reported by Peres *et al.* (2003). Briefly, mean final weight gains of fish fed different diets ranged from 12.1 to 31.8 g (Table 2). Fish fed the CSBM diet or the RSBM40 diet had similar weight gain, which was significantly higher than those of fish fed the other diets. Fish fed the RSBM0, RSBM5 or RSBM10 diet had similar weight gain but was significantly lower than the group fed the RSBM20 diet. Feed intake and feed efficiency ratio were reflective of weight gain. Survival rates varied from 96 to 100%, and no significant differences were observed.

Table 2 Mean weight gain, dry matter feed intake (FI), feed efficiency ratio (FER) and survival of channel catfish fed various experimental diets for 10 weeks[1] (from Peres *et al.* 2003)

Diets	Weight gain (g $fish^{-1}$)	FI (g DM $fish^{-1}$)	FER[2]	Survival %
CSBM	31.8 c	43.5 d	0.73 d	100.00
RSBM0	14.7 a	25.5 ab	0.58 bc	96.00
RSBM5	12.1 a	23.8 a	0.51 a	99.35
RSBM10	13.3 a	24.6 a	0.54 ab	99.35
RSBM20	18.4 b	29.5 b	0.62 c	100.00
RSBM40	30.9 c	38.7 c	0.80 e	100.00
Pooled SEM	1.2	1.5	0.02	0.90

CSBM, commercial soybean meal; RSBM, raw soybean meal; RSBM0, non-heat-treated RSBM; RSBM5, RSBM autoclaved at 130 °C and 22 psi for 5 min; RSBM10, RSBM autoclaved at 130 °C and 22 psi for 10 min; RSBM20, RSBM autoclaved at 130 °C and 22 psi for 20 min; RSBM40, RSBM autoclaved at 130 °C and 22 psi for 40 min.

[1] Column means with the same alphanumeric letters are not significantly different ($P > 0.05$).

[2] Feed efficiency ratio = (wet weight gain/dry feed fed).

Histologic samples from the stomach, proximal intestine, distal intestine, pancreas, liver and spleen of sampled fish in each treatment group were examined and compared with normal channel catfish tissue morphology described by Grizzle & Rogers (1976) and observed in samples from fish maintained on a fishmeal-based diet. In all of the SBM treatment groups, no histologic differences were noted in the proximal (Fig. 1) or distal (Fig. 2) intestinal samples when compared with other SBM treatment groups. The distal intestine only showed mild loss of supranuclear vacuolization when compared with the distal intestine of fish maintained on a fishmeal-based diet. Gastric gland necrosis was observed in many of the fish, exhibiting pyknosis and loss of cell-to-cell contact because of shrinkage. No significant differences in prevalence or severity were found among the treatment groups (Table 3). Pancreatic necrosis was also observed in all of the treatment groups, with increased severity among the CSBM and RSBM0 groups (Fig. 3). The pancreatic lesions were characterized by the presence of pyknotic acinar cells, loss of cell-to-cell contact, vacuolization and some liquefaction.

Each treatment group had fish with diffuse glycogen deposition in the liver (Fig. 3), although within each group there was considerable variation in the distribution and extent of glycogen deposition. Overall, there were no significant differences in glycogen deposition between the treatment groups. In a small number of fish, focal liver necrosis was observed, but no significant differences were noted between the treatment groups.

Considerable changes were also noted in the spleen (Fig. 4). Each treatment group exhibited multifocal deposition of a brownish-black pigment in the spleen, most notably associated with the splenic corpuscles. There was substantial variation within each treatment group, but no significant differences were noted between the treatments. Diffuse splenic congestion was also commonly observed; the most severe congestion was found among the CSBM, RSBM20 and RSBM40 treatment groups and often involved severe congestion of the peripheral blood sinuses, rupture of the splenic capsule and haemorrhage. Splenic congestion was lowest for the RSBM0 treatment group; a significant difference in severity was observed only between the RSBM20 and RSBM40 treatment groups and the RSBM0 treatment group.

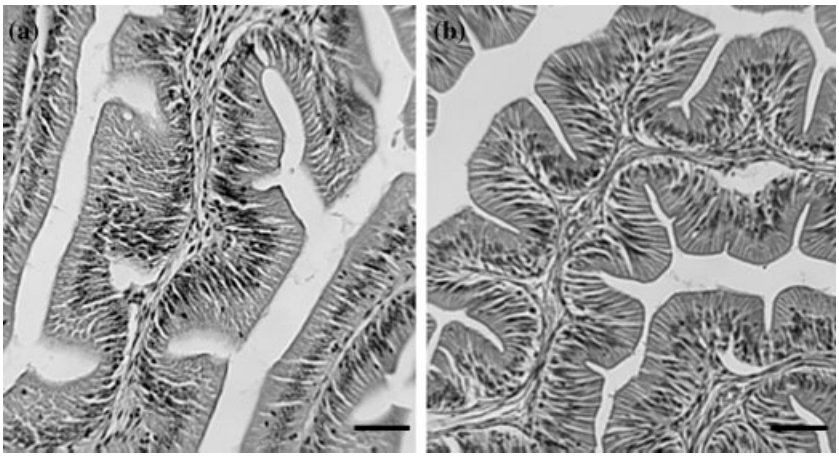

Figure 1 Representative histologic sections from fingerling channel catfish fed fishmeal or soybean meal. (a) Proximal intestine sample from fingerling channel catfish fed a fishmeal-based diet. Bar = 80 μm. (b) Proximal intestine sample showing structure from fish fed commercial soybean meal (CSBM). This section is representative of proximal intestinal structure found in all groups fed soybean meal-based diets. Bar = 110 μm.

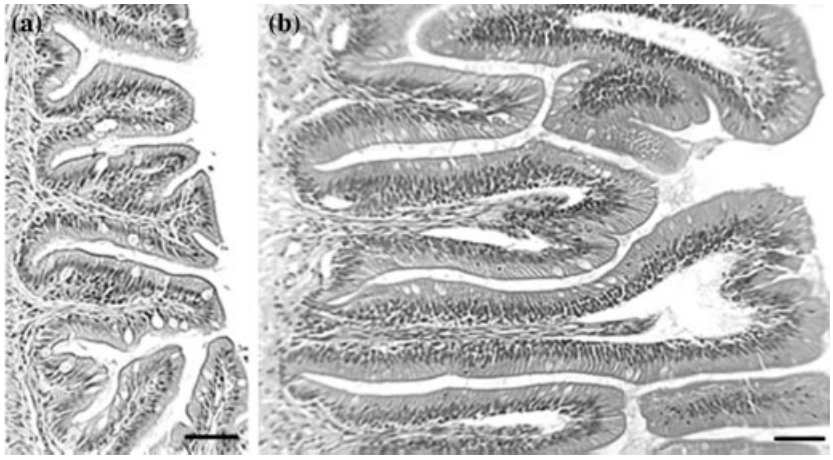

Figure 2 Representative histologic sections from fingerling channel catfish fed fishmeal or soybean meal. (a) Distal intestine sample from fingerling channel catfish fed a fishmeal-based diet. Bar = 62 μm. (b) Distal intestine sample showing structure from fish fed raw, non-heat-treated soybean meal (RSBM0). This section is representative of distal intestinal structure found in all groups fed soybean meal-based diets. Section lacks histologic changes such as inflammation and blunting of villi often found in other species of fish fed soybean meal. Mild alterations in vacuolization of villi are often present when compared with sections from fish maintained on fishmeal-based diets. Note there are no differences in the presence of lymphocytes, granular cells and macrophages in the intestinal mucosa of fish fed fishmeal-based diet or RSBM0. Bar = 52 μm.

Discussion

Because RSBM contains a number of heat-labile anti-nutritional factors, it must be heat-treated before use in fish feed. Some of the most commonly studied anti-nutritional factors are the trypsin inhibitors (TI). High levels of TI are known to hinder growth rate, feed efficiency and survival of some fish species (Viola *et al.* 1983; Wilson & Poe 1985). However, previous studies have suggested that SBM with a TI content of 1–5 mg g^{-1} is suitable for aquaculture species (Wilson & Poe 1985; Olli & Krogdahl 1994). Peres *et al.* (2003) measured the levels of TI in heat-treated RSBM used in this study (Table 1) and found that RSBM heat-treated for 40 minutes (RSBM40) was adequate to decrease the TI to a level adequate for use in catfish feed. In that study, the low TI level of the CSBM and RSBM40 treatment groups corresponded to higher weight gain, feed intake and feed efficiency than in the non-heat-treated RSBM and RSBM treatment groups heat-treated for less than 40 minutes.

In this study, the histologic changes in channel catfish did not appear to be related to RSBM heat-treatment or to TI levels. For example, liver glycogen deposition was observed in all treatment groups, but no significant differences were noted. Peres *et al.* (2003) found that channel catfish fed CSBM and RSBM40 diets had increased whole body protein but significantly decreased hepatosomatic index (ratio of liver

Table 3 Trypsin inhibitor (TI) content of commercial soybean meal (CSBM) and raw soybean meal (RSBM) heated for various time periods, and corresponding severity scores for histologic observations of various tissues of fingerling channel catfish fed these diets for 10 weeks

		Severity score[2]			
Diet	TI[1]	Liver glycogen	Gastric necrosis	Pancreatic necrosis	Splenic congestion
CSBM	4.00	1.33 a	0.44 a	2.00 a	2.11 ab
RSBM0	38.96	1.22 a	1.33 a	1.78 ab	1.44 a
RSBM5	35.00	0.94 a	0.89 a	0.44 c	1.67 ab
RSBM10	40.26	0.89 a	0.89 a	0.89 bc	1.72 ab
RSBM20	19.21	1.50 a	0.67 a	0.22 c	2.39 b
RSBM40	<1.05	1.33 a	1.11 a	0.67 c	2.33 b
Pooled SEM		0.10	0.14	0.14	0.12

CSBM, commercial soybean meal; RSBM, raw soybean meal; RSBM0, non-heat-treated RSBM; RSBM5, RSBM autoclaved at 130 °C and 22 psi for 5 min; RSBM10, RSBM autoclaved at 130 °C and 22 psi for 10 min; RSBM20, RSBM autoclaved at 130 °C and 22 psi for 20 min; RSBM40, RSBM autoclaved at 130 °C and 22 psi for 40 min.

[1] Trypsin inhibitor content measured as mg g^{-1} sample (as is basis). Values presented in Peres *et al.* (2003).

[2] Severity score (mean ± SEM) as determined by distribution and severity of histologic changes in observed organs. Means with the same alphanumeric letters are not significantly different ($P > 0.05$).

weight to body weight). Given the equivocal liver glycogen deposition among the different treatment groups in this study, our findings further support that the decreased hepatosomatic index of the CSBM and RSBM40 treatment groups was a factor of the significantly increased weight gain and protein deposition rather than decreased liver weight and glycogen storage.

Some necrotic lesions were noted within the liver and pancreas. Few hepatic lesions were observed, while existing changes were focal with only one altered area in each affected fish and no significant differences were assessed between the treatment groups. Pancreatic necrosis was noted among all of the treatment groups, but it was significantly more common among the CSBM and RSBM0 treatment groups. Because the RSBM0 treatment group exhibited more severe pancreatic necrosis than the heat-treated RSBM treatment groups, these findings may indicate that the component that induces pancreatic necrosis may be heat-labile. However, increased pancreatic necrosis in the (heat-treated) CSBM treatment group does not necessarily support this conclusion, and thus other heat-stable compounds present in SBM may also be responsible for these changes.

All treatment groups exhibited splenic pigment deposition and congestion. The brownish-black pigment was characteristic of melanin and may have been deposited as a reaction to a nutritional component. The congestion was moderate-to-severe in most treatment groups, with the highest severity score found among the CSBM, RSBM20 and RSBM40 treatment groups. Although significant differences in severity were observed only between the RSBM20 and RSBM40 treatment groups and the RSBM0 treatment group, the severity scores tended to increase with increasing heating duration. Thus splenic congestion may be caused by compounds other than heat-sensitive anti-nutritional factors. In addition, these findings still suggest that longer RSBM heat-treatments result in pooling of blood in the spleen. Peres *et al.* (2003) found that there were no significant differences in hematocrit among the CSBM, non-heat-treated RSBM and heat-treated RSBM treatment groups. This would suggest that the splenic congestion does not cause an apparent peripheral blood anaemia. However, the congestion may be problematic if it is accompanied by haemorrhage.

Previously, researchers have only evaluated the gastrointestinal histology of fish fed SBM and have observed different outcomes. Several researchers have found significant inflammation, decrease in vacuoles in the intestinal epithelium and blunting of villi in the proximal and distal intestines of salmonids fed diets with 250–300 g kg^{-1} SBM (Rumsey *et al.* 1995; Baeverfjord & Krogdahl 1996), and these changes have been observed irrespective of heat-treatment (van den Ingh *et al.* 1996). In contrast, Grisdale-Helland *et al.* (2002)

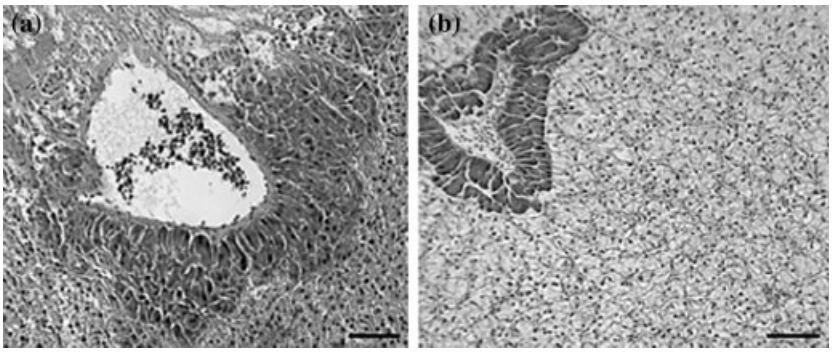

Figure 3 Representative histologic sections from fingerling channel catfish fed soybean meal for 10 weeks. (a) Pancreatic sample from RSBM20 group showing severe liquefactive necrosis of acinar cells adjacent to hepatic tissue with minimal glycogen deposition. Bar = 40 μm. (b) Liver sample from CSBM group exhibiting extensive glycogen deposition in hepatocytes. Bar = 80 μm.

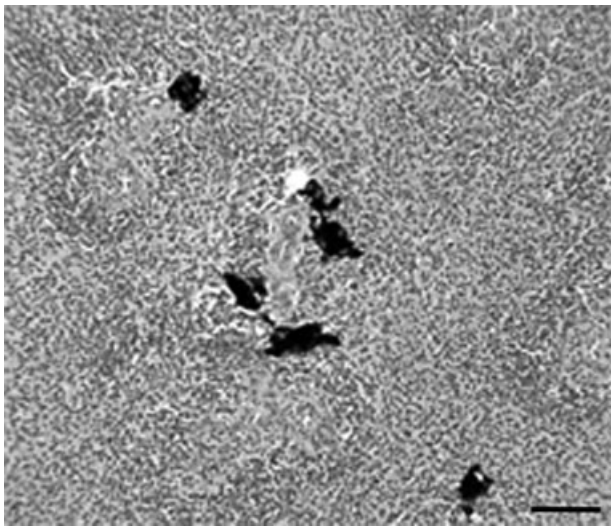

Figure 4 Representative histologic sections from fingerling channel catfish fed soybean meal for 10 weeks. Spleen sample from RSBM20 group showing severe diffuse congestion and copious brownish-black pigment deposition around splenic corpuscles. Bar = 100 μm.

indicated that no alterations in intestinal morphology were found in Atlantic halibut fed up to 360 g kg^{-1} full-fat SBM. In the study here, only a mild decrease in vacuolization in the distal intestine was observed when compared with the distal intestine of fish maintained on a fishmeal-based diet. There were no significant differences in vacuolization of the distal intestine when the RSBM groups were compared with each other and with the CSBM group. Furthermore, no other lesions or inflammation were noted within the proximal or distal intestines of the channel catfish fed 450 g kg^{-1} defatted CSBM, RSBM0 or heat-treated RSBM diets. Although inflammatory cells were observed associated with the mucosa of the proximal and distal intestines, the numbers of lymphocytes, granular cells and macrophages observed here were within normal limits for the channel catfish intestine (Gammon 1970; Krementz & Chapman 1975; Grizzle & Rogers 1976). Nonetheless, each treatment group exhibited mild gastric gland necrosis in the stomach sections, but no significant differences were observed between the treatment groups. These findings indicate that channel catfish may be affected by one or more non-heat-labile components that affect other internal organs but not necessarily the intestines, or that channel catfish may be more resistant to the effects of anti-nutritional factors present in SBM. Indeed, species differences may be important in the apparent effects of the SBM (Refstie *et al.* 2000; Peres *et al.* 2003).

Several compounds have been implicated in the generation of intestinal lesions in fish fed SBM diets. These compounds include lectins (Buttle *et al.* 2001), glycinin or β-conglycinin (Rumsey *et al.* 1994) and alcohol-soluble components like saponines or oligosaccharides (van den Ingh *et al.* 1996), and they may be first suspected as the SBM components that mildly affect the gastric gland, pancreas, or spleen. Some of these compounds may be discounted at present, because of their mode of action. For example, lectins are heat-labile, and if they were responsible for the observed changes, significant differences would have been seen between the non-heat-treated and the heat-treated treatment groups. Lectins can be further discounted because they appear to have specificity for a carbohydrate expressed in the upper villi of the distal intestine in salmonids (Buttle *et al.* 2001) and presumably would not affect the gastric glands, pancreas or spleen. Glycinin and β-conglycinin have also been implicated as factors in intestinal changes because of an induced inflammatory response (Rumsey *et al.* 1994), but no inflammatory responses were seen in the channel catfish histology samples. Nonetheless, compounds such as the ones listed here cannot be completely ruled out, because their effects may manifest differently in salmonids and channel catfish because of species and environmental differences. Further study would be needed to characterize the SBM components important to channel catfish health.

While the data in this study indicates the histologic changes in channel catfish fed CSBM, RSBM and heat-treated RSBM are generally equivocal, perhaps the most important determination is that channel catfish fed these diets do not develop alterations in intestinal morphology as severe as salmonids. Our research shows that juvenile channel catfish fed diets containing up to 450 g kg^{-1} non-heat-treated RSBM for 10 weeks had significantly reduced weight gain, feed intake and feed efficiency ratio (Peres *et al.* 2003), but did not develop severe histologic changes or intestinal lesions as have been reported in salmonids. This indicates that channel catfish can tolerate higher dietary anti-nutritional factors than salmonids. Studies with longer duration of feeding and using fishmeal- or soybean protein concentrate-based diets as the control are needed to define and characterize histologic changes in various organs.

Acknowledgements

This research was supported by grants from the United States Department of Agriculture – Agricultural Research Service (CRIS Project no. 6420-32000-011-00D) and Fundação para a Ciência e Tecnologia, Portugal (BPD/22088/99). The authors wish to thank Dr Paul R. Bowser and Dr Delbert M. Gatlin III for their reviews of this manuscript and Dr. Dehai Xu for his statistical help.

References

Baeverfjord, G. & Krogdahl, A. (1996) Development and regression of soybean meal induced enteritis in Atlantic salmon, *Salmo salar* L., distal intestine: a comparison with the intestines of fasted fish. *J. Fish Dis*., **19,** 375–387.

Beckmann, J. & Pfeffer, E. (1989) Hydrothermically treated fullfat soybeans in rainbow trout (*Salmo gairdneri*). In: *Recent Advances of Research in Antinutritional Factors in Legume Seeds* (Huisman, J., van der Poel, A.F.B. & Liener, I.E. eds), pp. 99–102. Pudoc, Wageningen.

Buttle, L.G., Burrells, A.C., Good, J.E., Williams, P.D., Southgate, P.J. & Burrells, C. (2001) The binding of soybean agglutinin (SBA) to the intestinal epithelium of Atlantic salmon, *Salmo salar* and rainbow trout, *Oncorhynchus mykiss,* fed high levels of soybean meal. *Vet. Immunol. Immunopathol*., **80,** 237–244.

Dimes, L.E., Haard, N.F., Dong, F.M., Rasco, B.A., Forster, I.P., Fairgrieve, W.T., Arndt, R., Hardy, R.W., Barrows, F.T. & Higgs, D.A. (1994) Estimation of protein digestibility: II. *In vitro* assay of protein in salmonid feeds. *Comp. Biochem. Physiol*., **108A,** 363–370.

Gammon, R.L. (1970) The gross and microanatomy of the digestive tract and the pancreas of the channel catfish, *Ictalurus punctatus*. MS Thesis, Kansas State University, Manhattan, KS, USA.

Grisdale-Helland, B., Helland, S.J., Baeverfjord, G. & Berge, G.M. (2002) Full-fat soybean meal in diets for Atlantic halibut: growth, metabolism and intestinal histology. *Aquacult. Nutr*., **8,** 265–270.

Grizzle, J.M. & Rogers, W.A. (1976) *Anatomy and Histology of the Channel Catfish*. Agricultural Experiment Station, Auburn University, Auburn, AL, USA.

van den Ingh, T.S.G.A.M., Krogdahl, A., Olli, J.J., Hendriks, H.G.C.J.M. & Konikx, J.G.J.F. (1991) Effects of soybean-containing diets on the proximal and distral intestine in Atlantic salmon (*Salmo salar*): a morphological study. *Aquaculture*, **94,** 297–395.

van den Ingh, T.S.G.A.M., Olli, J.J. & Krogdahl, A. (1996) Alcohol-soluble components in soybeans cause morphological changes in the distal intestine of Atlantic salmon, *Salmo salar* L. *J. Fish Dis*., **19,** 47–53.

Kratzer, F.H., Bersch, S. & Vohra, P. (1990) Evaluation of heat-damage to protein by coomassie blue G dyebinding. *J. Food Sci*., **55,** 805–807.

Krementz, A.B. & Chapman, G.B. (1975) Ultrastructure of the posterior half of the intestine of the channel catfish, *Ictalurus punctatus*. *J. Morph*., **145,** 441–482.

Krogdahl, A. & Holm, H. (1983) Pancreatic proteinases from man, trout, rat, pig, cow, mink and fox. Enzyme activities and inhibition by soybean and lima bean proteinase inhibitors. *Comp. Biochem. Physiol*., **74B,** 403–409.

Lim, C. & Akiyama, D.M. (1991) Full-fat soybean meal utilization by fish. In: *Proceedings of the Aquaculture feed Processing and Nutrition Workshop, Thailand and Indonesia* (Akiyama, D.M. & Tan, R.K.H. eds), pp. 188–189. American Soybean Association, Singapore.

Lim, C. & Dominy, W. (1989) Utilization of plant protein by warmwater fish. In: *Proceedings of the World Congress on Vegetable Protein Utilization in Human Foods and Animal Feedstuff* (Applewhite, T.H. ed.), pp. 245–251. AOCS Press, Champaign, IL, USA.

Luna, L.G. (1968) *Manual of Histological Staining Methods of the Armes Forces Institute of Pathology*. McGraw Hill, New York, NY, USA.

Olli, J.J. & Krogdahl, A. (1994) Nutritive value of four soybean products as protein sources in diets for rainbow trout (*Oncorhynchus mykiss,* Walbaum) reared in fresh water. *Acta Agric. Scand. A Anim. Sci*., **44,** 185–192.

Peres, H., Lim, C. & Klesius, P.H. (2003) Nutritional value of heat-treated soybean meal for channel catfish (*Ictalurus punctatus*). *Aquaculture*, **225,** 67–82.

Qin, G.X., Verstegen, M.W.A. & van der Poel, A.F.B. (1998) Effect of temperature and time during steam treatment on the protein quality of full-fat soybean from different origins. *J. Sci. Food Agric*., **77,** 393–398.

Refstie, S., Korsoen, O.J., Storebakken, T., Baeverfjord, G., Lem, I. & Roem, A.J. (2000) Differing nutritional responses to dietary soybean meal in rainbow trout (*Onchorynchus mykiss*) and Atlantic salmon (*Salmo salar*). *Aquaculture*, **190,** 49–63.

Rumsey, G.L., Siwicki, A.K., Anderson, D.P. & Bowser, P.R. (1994) Effect of soybean protein on serological response, non-specific defense mechanisms, growth and protein utilization in rainbow trout. *Vet. Immunol. Immunopathol*., **41,** 323–339.

Rumsey, G.L., Endres, J.G., Bowser, P.R., Earnest-Koons, K.A., Anderson, D.P. & Siwicki, A.K. (1995) Soy protein in diets of rainbow trout: effects on growth, protein absorption, gastrointestinal histology and nonspecific serologic and immune response. In: *Nutrition and Utilization Technology in Aquaculture* (Lim, C. & Sessa, D.J. eds), pp. 166–188. AOCS Press, Champaign, IL, USA.

Viola, S., Mokady, S. & Arieli, Y. (1983) Effects of soybean processing methods on the growth of carp (*Cyprinus carpio*). *Aquaculture*, **32,** 27–38.

Wilson, R.P. & Poe, W.E. (1985) Effects of feeding soybean meal with varying trypsin inhibitor activities on growth of fingerling channel catfish. *Aquaculture*, **46,** 19–25.