ResearchGate

See discussions, stats, and author profiles for this publication at: https://www.researchgate.net/publication/262527467

Histochemistry and Ph Characterization of the Gastrointestinal Tract of Nile Perch Lates niloticus

Article · January 2014

DOI: 10.5829/idosi.wjfms.2014.06.02.82216

CITATIONS
2

READS
402

5 authors, including:

Victoria Tibenda Namulawa
National Agricultural Research Organization
20 PUBLICATIONS **90** CITATIONS
SEE PROFILE



Charles Drago Kato
Makerere University
84 PUBLICATIONS **254** CITATIONS
SEE PROFILE

Justus Rutaisire
National Agricultural Research Organization
33 PUBLICATIONS **168** CITATIONS
SEE PROFILE

Some of the authors of this publication are also working on these related projects:

Project
Studies on the status of Uganda's aquatic health View project

Project
Immunoparasitology Project View project

All content following this page was uploaded by Victoria Tibenda Namulawa on 23 May 2014.

The user has requested enhancement of the downloaded file.

World Journal of Fish and Marine Sciences 6 (2): 162-168, 2014
ISSN 2078-4589
© IDOSI Publications, 2014
DOI: 10.5829/idosi.wjfms.2014.06.02.82216

Histochemistry and Ph Characterization of the Gastrointestinal Tract of Nile Perch *Lates niloticus*

[1]V.T. Namulawa, [2]C.D. Kato, [2]E. Nyatia, [2]M. Kiseka and [3]J. Rutaisire

[1]Aquaculture Research and Development Centre, P.O. Box, 530, Kampala, Uganda
[2]College of Veterinary Medicine,
Animal Resources and Biosecurity, P.O. Box 7026, Kampala, Uganda
[3]National Agricultural Research Organization, P.O. Box 295, Entebbe, Uganda

Abstract: Investigations were undertaken to establish the histochemistry and pH of the Nile perch gut, using standard methods. Results revealed that the oral cavity and oesophagus epithelia were lined with goblet cells containing both neutral carboxylated mucins and acidic sialomucins. The stomach apical cells exclusively contained neutral carboxylated mucins, while the ceace and intestinal epithelia were rich in acidic sulfated glycoproteins and sialomucins. Investigation further revealed that the pH in the Nile perch gut is relatively acidic and that stomach fullness has a significant correlation with the degree of acidity in the different gut regions. These observations suggest that the nature of mucins and pH of the Nile perch gut have a great influence on the functioning of the digestive system in relation to its diet.

Key words: Mucins · pH · Gastrointestinal Tract · Nile Perch

INTRODUCTION

Nile perch is a freshwater species in Uganda and in the East African region. The fish is popular for its white flesh, omega 3 and rich amino acids [1, 2]. These attributes led to the aggressive harvest of this fish for the regional and international markets, a practice that resulted into a great decline of its wild populations [3]. Several strategies to revamp the species have been suggested; including aquaculture. However, no information is available about the functional physiology of the digestive system of Nile perch. Such information is crucial in guiding the development of artificial diets for the intended aquaculture species.

Digestion in fish is a function of the physical-chemical environment in the gastrointestinal tract, which mainly depends on the mucins and pH that determine the suitability of the environment for digestive enzymes activity [4-9]. Therefore, information about the physiology of the digestive tract is important because it provides insights into the ability of a fish species to digest feedstuffs. This study is therefore vital to the artificial diet formulation and manufacturing process for any new aquaculture species [10], since it guides the suitable dietary ingredients.

The purpose of this study was to characterize the gut pH and to investigate the mucins and their specific location in the Nile perch gut. Results from this study will further explain the feeding behavior in Nile perch and provide information to guide the formulation of artificial diets for the culture of Nile perch.

MATERIALS AND METHODS

Samples Collection: Wild Nile perch samples were collected from the Northern side of Lake Victoria in Uganda (32° 26' 15″E, 00° 2' 49″N) using beach seines. The fish were starved for twenty-four hours under freshwater and a continuous oxygen supply. Investigations were performed on guts obtained from Nile perch measuring between 1cm and 40 cm (TL). 24 fish samples were considered for this study; they were divided into eight size classes (1- 5, 6-10, 11-15, 16-20, 21-25, 26- 30, 31-35, 36-40 cm-TL), with three samples representing each class.

Corresponding Author: Namulawa, V.T., Aquaculture Research and Development Centre, P.O. Box, 530, Kampala, Uganda.

Histochemical Analysis: Tissue sections (5µm) from different regions (oral cavity, oesophagus, stomach, caeca and intestine) of the Nile perch gut were processed using standard histological procedures described by [11].

Stomach Fullness and Gut pH: The fish were anesthetized with an over doze of using clove oil before dissection to extract the gut. Stomach fullness was determined following procedures applied by [12] in addition to those by [13]. This was done by pressing the stomach from its anterior end (the cardiac region) towards its posterior (the blind end). Stomach fullness was rated as: empty, quarter, half, three quarters and full. In this method, each stomach was awarded points in relation to its fullness from 0 to 4 as follows: 0 = Empty stomach; 1 = ¼ full stomach; 2 = ½ full stomach; 3 = ¾ full stomach; and 4 = > ¾ full stomach. The effect of stomach fullness on the gut pH was assessed following procedures used by [14]. Dietary and tissue adherent pH were determined by making slurry of the food (chyme) and lumen tissue from the stomach, pyloric caeca and intestine. Distilled water was separately added to each extract at a ratio of 1:1. pH was then measured using calibrated pH meter.

Statistical Analysis: SPSS version 20 was used to analyse the data. Comparison across the gut sections was done using Tukey`s Multiple Comparison Test set at $P<0.05$. The relationship between gut pH and stomach fullness amongst the samples was analysed using Pearson correlation matrix set at a $P<0.05$.

RESULTS

Histochemistry: Histochemical investigations revealed the presence of neutral, acidic sialomucins and acidic sulformucins in the goblet cells in the oral cavity (Figures 1) and oesophagus (Figure 2) because these stained positively with AB (pH 1.0), AB (pH 2.5) and PAS. The stomach epithelial cells (Figure 3) showed presence of only neutral mucins which stained positively with PAS; however the mucosal cells in the stomach registered a weak presence of AB positive mucins. Investigations further indicated the presence of acidic sulformucins and acidic sialomucins in the goblet cells of the caeca (Figure 4) and in the intestine (Figure 5) which stained strongly positive with AB (pH 2.5).

Effect of Stomach Fullness on the Gut pH: The stomach in Nile perch was acidic with pH levels ranging between 4.36±1.11 to 6.77±0.72; the gut pH then tended to neutral towards the hind intestine (Table 1). The post-hoc Tukey's HSD tests showed no significant difference ($p>0.05$) in the pH of the digesta found in the anterior intestine and rectum. However, a significant difference was observed in the pH of the digest found in the stomach, ceca and middle intestine at different degrees of stomach fullness. All the low pH values in the empty and ¼ full stomachs were generated from fish that had digesta in their intestines, while the high pH readings in empty stomachs were only observed in fish that did not have digesta in their intestines.

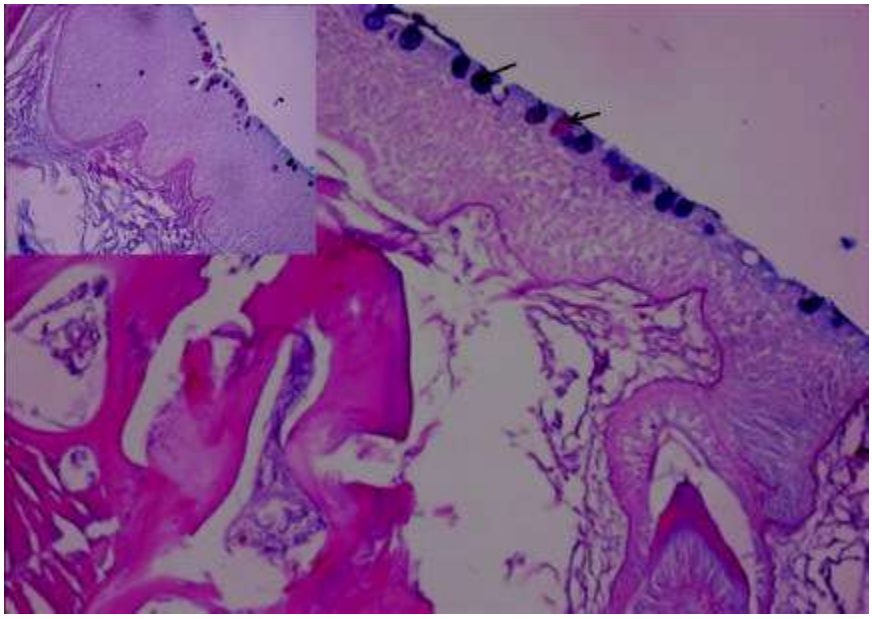

Fig. 1: Oral cavity of Nile perch showing the mucins in the goblet cells (arrow). AB & PAS (X 400)

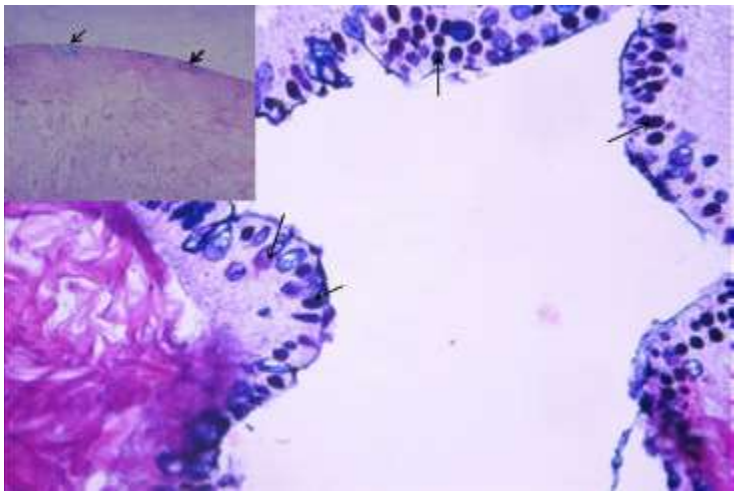

Fig. 2: Sections of the oesophagus of Nile perch showing the mucins in the goblet cells (arrow). AB & PAS (X 400)

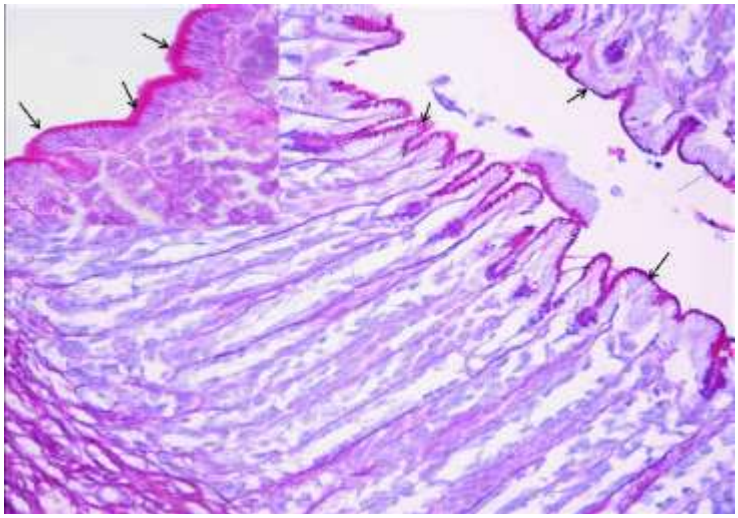

Fig. 3: Stomach of Nile perch showing the mucins in the epithelial cells (arrow). AB & PAS (X 400)

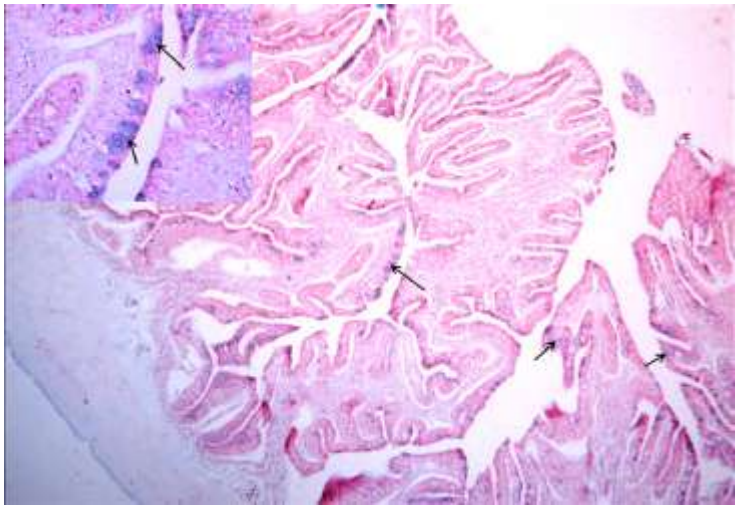

Fig. 4: Caeca of Nile perch showing the mucins in the goblet cells (arrow). AB & PAS (X 400)

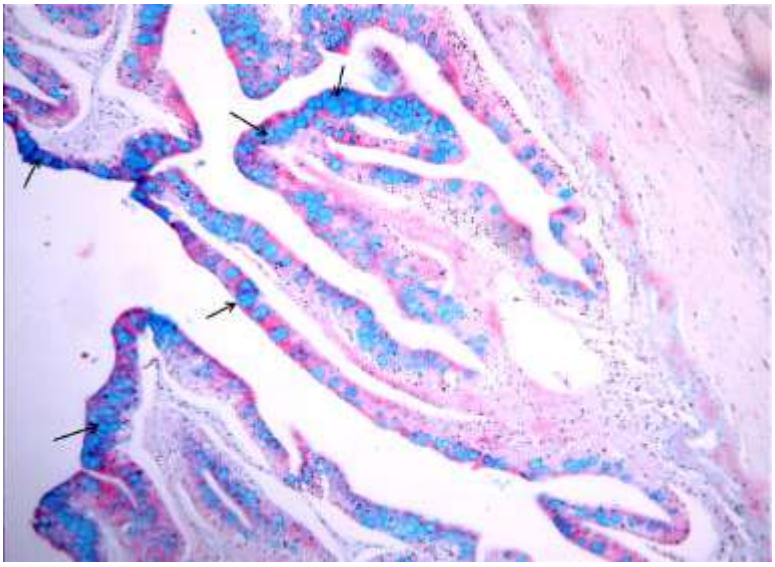

Fig. 5: Intestine Nile perch showing the mucins in the goblet cells (arrow). AB & PAS (X 400)

Table 1: pH ranges in different sections of the Nile perch gut at different degrees of stomach fullness

	pH range in the different gut sections				
Degree of Stomach fullness	Stomach	Caeca	Anterior intestine	Middle intestine	Hind intestine
0 (Empty)	6.66±0.07	6.63±0.08	6.69±0.10	6.75±0.09	6.79±0.10
1 (¼ full)	6.06±0.12	6.56±1.82	6.62±0.13	6.65±0.18	6.66±0.18
2 (½ full)	5.98±0.14	6.17±0.16	6.45±0.16	6.58±0.13	6.57±0.12
3 (¾ full)	5.84±0.16	6.23±0.13	6.55±0.11	6.81±0.09	6.89±0.10
4 (¾ full)	6.07±0.07	6.39±0.05	6.55±0.06	6.95±0.06	6.76±0.07

Comparisons of the relationship between gut pH and stomach fullness amongst the samples, using Pearson correlation matrix revealed a significant correlation between stomach fullness and stomach pH (r=0.337), ceca pH (r=0.214) and middle intestine pH (r=0.235). However, no correlation was observed between stomach fullness and the pH in the anterior intestine (r=0.106) and that in the hind intestine (r=0.031) at P=0.05.

DISCUSSION

Neutral (PAS positive) and acidic sialomucins and sulfomucins (AB pH 2.5, AB pH 1.0 respectively) were present in the oral cavity and oesophagus of *L. niloticus*. Similar mucins were described in the same region in *Trichomycterus brasiliensis* [11] *Solea senegalensis* [15] *Diplodus sargus* [16], *Esox lucius*, *Silurus glanis* [7] *Thunnus thynnus* [8] and in *Cynoscion guatucupa* [17]. These mucins are probably important for lubrication [18] and protection [19], since Nile perch is a swallower whose buccal cavity requires maximum protection and minmum friction during ingestion. The mucins are therefore not important for digestion, since no enzyme secreation has been reported in oral cavity and anterior section of the oesophagus in fish [20].

High levels of neutral glycoconjugates (intense PAS staining) in the epithelia cells and low levels of sulfated glycoconjugates (weak AB 1.0, 2.5 stainng) in the mucosa were observed in the stomach of *L.niloticus*. Similar observations have been reported in the stomach of *Umbrina cirrosa* [6] and *Halobatrachus didactylus* [20]. The neutral glucoconjugates produced by the stomach epithelum of Nile perch may be important for regulating the pH in the stomach [11], making it suitable for specific enzyme activity and for forming a visco-elastic barrier that provides physical protection to the underlying mucosa against hdyrochloric acid and proteolytic enzymes produced in the gastric glands [22]. These neutral mucins could also be important in the absorption of easily digestible substances such as double sugars and fatty acids [15]; while the sulfated glycoconjugates observed in the mucosa, could form

Table 2: pH ranges in the guts of different organisms

Organism	Main food (s) in the diet	pH	Reference
Tilapia guineensis	Leafy material and Blue green algae	2.0 (stomach)	[29]
Grey mullets *Liza falcipinnis*	Algae	3.3-8.5 (gut)	[30]
Red sea surgeonfish *Acanthurus nigrofuscus*	Algae	2.5-7.5 (gut)	[31]
Rainbow trout *Oncorhynchus mykiss*	Fish	2.6-8.65 (gut)	[32]
Rat *Rattus norvegicus*	Seeds	1.3-7.95 (gut)	[32]
Burmese python *Python molurus*	Mammals and small birds	1.5-7 (gut)	[33]
Bearded vulture *Gypaetus barbatus*	Bones	0.8-1.0 (stomach)	[34]

complexes with proteinases as a way of buffering and stablizing them [23]. The presence of diverse glycocogugates in the Nile perch stomach therefore facilitates chemical digestion.

Intense staining of AB pH 2.5, 1.0 and very weak PAS staining were observed in the caeca and intestinal epithelal regions of Nile perch, indicating high levels of acidic sialo-and sulfated glycoconjugates, together with very low levels of neutral glycoconjugates. Similar observations have been reported in the intestine of *Oncorhynchus mykiss* [18], *Orthrias angorae* [24], *Tilapia spilurus* and *Mylio cuvieri* [25]. These mucosubstances have been found to provide cofactors required for enzymatic breakdown of food in teleost fishes [26]. Sialomucins and sulfomucins have been reported to increase gut resistance against bacterial degradation [27]; acidic mucins have been found to protect the intestinal epithelium against the degrative action of glycosidases [28] mainly found in the intestine. The presence of these different types of glycoconjugates in the intestinal region of Nile perch suggests that this region provides a suitable environment that facilates effictive chemical digestion at the appropraite pH.

Investigations from this study revealed that the Nile perch stomach is generally acidic, with the gut pH tending to neutral towards the hind intestine (Table 1). The present results suggest that acid secretion in the Nile perch gut probably intensifies as the digestion process continues (Table 1), in order to create an effectively acidic environment to enhance the performance of the protelytic enzymes and to breakdown the prey scales and bones. This could explain why the stomach pH in Nile perch continues to decrease, as the stomach gets less full. The pH of the digesta along the tract after leaving the stomach was mildly acidic (Table 1), probably because of the neutralization effect of the bile poured in this region. This also indicates the optimum pH range within which the enzymes in the gut of Nile perch.

The low pH observed in the Nile perch stomach (Table 1) is probably due to the presence of the oxynticopeptic cells which specialize in acid production among other functions [31, 35] and which occur in reptiles [36] and in birds [37]. This low acidity could partly explain the efficiency with which *L. niloticus* completely digests the whole fish it swallows without mastication, including the scales and bones, as observed in other predators [38]. The need for the gastric acid in the breakdown of prey could also be explained by the significant correlation observed between the stomach fullness and the digesta pH in the stomach. This suggests that as soon as food is detected in the stomach, the environment is instantly stimulated to a low pH [14, 39]. This observation is close to that observed in the salmonids, where the amount of pepsin and acid in the gut was seen to be proportional to the degree of distension of the stomach [40].

The pH ranges observed in the Nile perch gut in this study are close to those observed in the rainbow trout gut and in some algae-eating tilapines, but are higher than those observed in the bone-eating vultures and rats (Table 2).

CONCLUSION

The study shows variation in mucosubstances across the Nile perch gut, indicating the functional roles played by the different segments as regards digestive function. It also reveals the acidic nature of the Nile perch stomach and intestinal contents, suggesting its specialization in digesting protein rich food items.

ACKNOWLEDGEMENTS

Authors greatly appreciate the financial support from the World Bank through the Uganda National Council for Science and Technology.

REFERENCES

1. Bambona, A., 2002. Marketing opportunities of Ugandan Nile perch (Lates niloticus) in the European Union (EU). Fisheries Training Program. Skulagata 4120, Reykjavik, Iceland.

2. Mohammed, M.O., 2012. Economic importance of the Nile perch (Lates niloticus L). Int. J. Environ. Biol., 2(1): 79-91.
3. Everson, I., R. Kayanda and A.T. Munyaho, 2013. Comparing ecosounder efficiency using field observations. Lake Reserv. Manage., 18(2): 167-177.
4. Garrido, M.V., M.I. Torres and M.A. Equisoain, 1998. Histologcal, histochemical and ultrastructural analysis of the gastric mucosa in Oncorhynchus mykiss. Aquaculture, 115: 121-132.
5. Gum, J.R., J.W. Hicks, A.M. Gillespie, E.J. Carlson, L. Komuves, S. Karnik and Y.S. Kim, 1999. Goblet cell-specific expression mediated by the MUC2 mucin gene promoter in the intestine of transgenic mice. Ameri. J. Physiol., 276(3): G666-G676.
6. Pedini, V., C. Dall'Aglio, F. Parillo and P. Scocco, 2005. Glycoconjugate distribution in gastric fundic mucosa of Umbrina cirrosa L. revealed by lectin histochemistry. J. Fish Biol., 66: 222-229.
7. Petrinec, Z., S. Nejedli, S. Kuzir and A. Opacak, 2005. Mucosubstances of the digestive tract mucosa in northern pike (Esox lucius L) and European catfish (Silurus glanis L.). Vet. Arhiv., 75: 317-327.
8. Kozaric, Z., S. Kuzir, Z. Petrinec, E. Gjurcevic and N. Baturina, 2007. Histochemistry of complex glycoproteins in the digestive tract mucosaof Atlantic blue tuna (Thunnus thynnus L.), Vet. Arhiv., 77(5): 441-452.
9. Saadatfar, Z., D. Shahsavani and S. Khoshnegah, 2010. Development of stomach in Sturgeon (Acipenser persicus). J. Appl. Ani. Res., 37: 153-156.
10. Britz, P.J., 1995. The nutritional requirements of haliotis midae and development of a practical diet for abalone aquaculture. PhD thesis, Rhodes university, Grahamstown, South Africa.
11. Oliveira-Ribeiro, C.A. and E. Fanta, 2000. Microscopic morphology and histochemistry of the digestive system of a tropical freshwater fish Trichomycterus brasiliensis (Lutken) (Siluroidei, Trichomycteridae). Rev. Bras. Zootecn., 17: 953-971.
12. Ogutu-Ohwayo, R., 1993. The effects of predation by the Nile perch, *Lates niloticus* L. on the fishes of Lake Nabugabo, with suggestions for conservation of endangered endemic cichlids. Conser. Biol., 7: 701-711.
13. Berra, T. and D. Wedd, 2001. Alimentary canal anatomy and diet of the nurseryfish, Kurtus gulliveri (Perciformes: Kurtidae), from the Northern Territory of Australia. The Beagle Records of the Museum and Art Galleries of the Northern Territory, 17: 21-25.
14. Getachew, T., 1989. Stomach pH, feeding rhythm and ingestion rate in Orechromis niloticus L. (Pisces: Cichlidae) in Lake Aswas, Ethiopia. Hydrobiol., 174: 43-48.
15. Arellano, J.M., V. Storch and C. Sarasquete, 2001. A histological and histochemical study of the oesophagus and oesogaster of the Senegal sole, Solea senegalensis. Eur. J. Histochem., 45: 279-294.
16. Oritz-Delgado, J.B., M.J. Darias, J.P. Canavate, M. Yufera and C. Sarasquete, 2003. Organogenesis of the digestive tract in the white sea bream, Diplodus sargus. Histological and histochemical approaches. Histol. Histopathol., 18: 1141-1154.
17. Diaz, A.O., A.M. Gracia and A.L. Goldemberg, 2008. Glycoconjugates in the mucosa of the digestive tract of Cynoscion guatucupa: A histochemical study. Acta Histochem., 110: 76-85.
18. Khojasteh, S.M., F. Sheikhzadeh, D. Mohammadnejad and A. Azami, 2009. Histological, histochemical and ultrastructural study of the intestine of rainbow trout (Oncorhynchus mykiss). World Appl. Sci. J., 6 (11): 1525-1531.
19. Adikwu, M., 2006. Mucins and their potentials. Trop. J. Pharm. Res., 5(2): 581-582.
20. Smith, L.S., 1989. Digestive functions in teleost fishes. In J. Halver, & RW. Hardy, Fish Nutrition (Vols. 2nd Edition, 331-421). Academic Press, San Diego.
21. Desantis, S., F. Acone, S. Zizza, M. Deflorio, J.P. Fernandez, C. Sarasquete and G. Metrio, 2009. Glycohistochemical study of the toad fish Halobatrachus didactylus (Scheider, 1801) stomach. Sci. Mar., 73(3): 515-525.
22. Sarasquete, C., E. Gisbert, L. Ribeiro, L. Vieira and M.T. Dinis, 2001. Glycoconjugates in epidermal, branchial and digestive mucous cells and gastric glands of gilthead sea bream, Sparus aurata, Senegal sole *Solea senegalensis* and Siberian sturgeon Acipenser baeri development. Eur. J. Histochem., 45: 267-278.
23. Cao, X.J. and W.M. Wang, 2009. Histology and mucin histochemistry of the digestive tract of Yellow Catfish, Pelteobagrus fulvidraco. Anat. Histol. Embryol., 38: 254-261.
24. Suicmez, M. and E. Ulus, 2005. A study of the anatomy, histology and ultrastudture of the digestive tract of Orthrias angorae, Steindachner, 1897. Folia Biol., 53(1-2): 95-100.
25. Heyam, A.A., 2005. Some comparative histological studies on the alimentary tract of tilapia fish (Tilapia spilurus) and sea bream (Mylio cuvieri). Egypt J. Aquat. Res., 31: 387-397.

26. Delashoub, M., I. Pousty and S.M. Khojasteh, 2010. Histology of Bighead carp (Hypophthalmichthys nobilis) intestine. Global Veterinaria, 5: 302-306.
27. Cao, X.J., W.M. Wang and F. Song, 2011. Anatomical and histological charateristics of the intestine of the Topmouth culter (Culter alburnus). Anat. Histol. Embryol., 40: 292-298.
28. Carrasson, M., A. Grau, L.R. Dopazo and S. Crespo, 2006. A histological, histochemical and ultrastructural study of the digestive tract of Dentex dentex (Pisces, Sparidae). Histol. Histopathol., 21: 579-593.
29. Payne, A.I., 1978. Gut pH and digestive strategies in estuarine grey mullet (Mugilidae) and tilapia (Cichlidae). J. Fish Biol., 13(5): 627-629.
30. Lobel, P.S., 1981. Trophic biology of herbivorous reef fishes: alimentary pH and digestive capability. J. Fish Biol., 19(4): 365-397.
31. Montgomery, W.L. and P.E. Pollak, 1988. Gut anatomy and pH in a Red sea surgeon fish Acanthurus nigrofuscus. Mar. Ecol. Prog. Ser., 44: 7-13.
32. Sugiura, S.H., P.K. Roy and R.P. Ferraris, 2006. Dietary acidification enhances phosphorous digestibility but decreases H^+/K^+-ATpase expression in rainbow trout. J Exp. Biol., 209: 3719-3728.
33. Secor, S.M., 2008. Digestive physiology of the Burmese python: broad regulation of integrated performance. J. Exp. Biol., 211: 3767-3774.
34. Huston, D.C. and J.A. Copsey, 1994. Bone digestion and intestinal morphology of the bearded vulture. J. Raptor Res., 28(2): 73-78.
35. Ahmed, Y.A., A.A. El-hafez and A.E. Zayed, 2009. Histological and histochemical studies on the oesophagus, stomach and small intestine of Veranus niloticus. J. Vet. Anat., 2(1): 35-48.
36. Rebolledo, I.M. and J.D. Vial, 1978. Digestive system: Fine structure of the oxynticopeptic cell in the gastric glands of an elasmobranch species (Halaelurus chilensis). Anat. Rec., 193: 805-821.
37. Selvan, P.S., S. Ushakumary and G. Ramesh, 2008. Studies on the histochemistry of the proventriculus and gizzard of post-hatch guinea fowl (Numida meleagris). Int. J. Poult. Sci., 7: 1112-1116.
38. Kuz'mina, V.V and I.L. Golovanova, 2003. Contribution of prey proteinases and carbohydrases in fish digestion. Aquaculture, 234(1-4): 347-360.
39. Moriarty, D.J., 1973. The physiology of digestion of blue green algae in the cichlid fish, Tilapia nilotica. J. Zool., 171(l): 25-39.
40. Smith, L.S., 2004. Digestion in Teleost Fishes. Retrived from www.fao.org/docrep/x5738E/x57380e02. htm.

View publication stats